

**PATIENT**

Nakiva Cleveland

**PRESENTING CLINICAL SIGNS**

Presented for cough. Currently taking Levothyroxine, Gabapentin, and Trazodone. Abnormal PE/Chem/CBC/UA Results: No abnormal lung sounds. No murmur. Slightly underweight. On the x-ray, I am seeing an elevation of the thoracic trachea.

**SPECIES**

Canine

**RADIOGRAPHIC STUDY OF THE THORAX**

Right/left lateral and ventrodorsal views of the thorax totaling 3 images available for review.

**BREED**

Shiba Inu

**RADIOGRAPHIC FINDINGS**

A small fat opaque subcutaneous nodule is seen ventral to the xiphoid of the sternum within the thoracic wall.

**SEX**

NM

A mild dorsal kink of the precardial trachea is seen on both lateral views which is an incidental finding and linked to the patient's head position. No pathologic tracheal elevation is noted.

**AGE**

12 Years

The lungs are moderately inflated. A mild generalized bronchial lung pattern with occasional peribronchial cuffing is seen.

The cardiac silhouette is upright and thin. The pulmonary vasculature and caudal vena cava are thin as well. The vertebral heart score is 9.7. No abnormal mediastinal widening is noted.

The thoracic boundaries present within normal limits.

The stomach is postprandial.

**INTERPRETED BY**

Nele Eley, DVM  
Dr. med. Vet. DipECVDI

**RADIOGRAPHIC DIAGNOSIS**

- Mild generalized bronchial lung pattern.
- No radiographic evidence of tracheal or cardiovascular pathology.
- Small lipoma within the ventral thoracic wall.

**HOSPITAL NAME**

Grove Veterinary  
Clinic

**INTERPRETATION OF THE FINDINGS & FURTHER RECOMMENDATIONS**

The radiographic study reveals a mild generalized bronchial lung pattern. Differential diagnosis includes allergic/eosinophilic bronchopneumopathy and infectious bronchitis such as viral, bacterial, and parasitic. A clinical trial of treatment for bronchitis could be considered along with lung worm testing versus airway endoscopy with airway sampling for further definition.

**REFERRING VET**

Dr. Luna

**INVOICE**

56857

**DATE**

2-17-23



**PATIENT**

Nakiva Cleveland

**SPECIES**

Canine

**BREED**

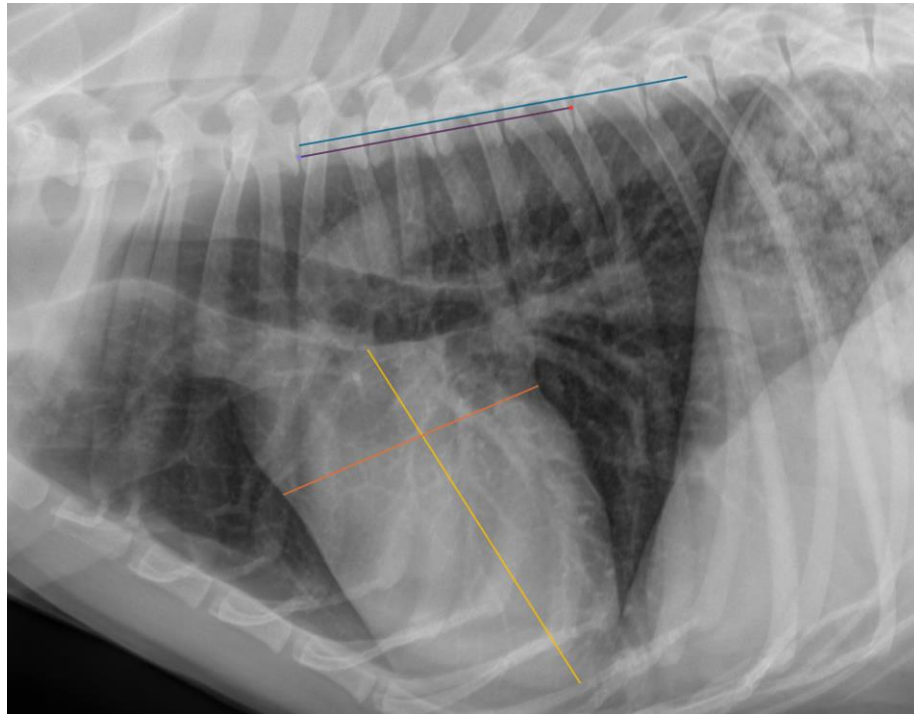
Shiba Inu

**SEX**

NM

**AGE**

12 Years



**INTERPRETED BY**

Nele Eley, DVM  
Dr. med. Vet. DipECVDI

The information and recommendations provided are based on the images presented by the referring veterinarian/sonographer. No evaluation can be communicated regarding pathology that was not visible in the image/video clips provided.

Thank you for this referral. If the clinical or image interpretation does not parallel your findings or if I can be of any further assistance please contact me.

**HOSPITAL NAME**

Grove Veterinary  
Clinic

**Nele Eley**, DVM, Dr. med. vet., DipECVDI  
European Specialist in Veterinary Diagnostic Imaging, Cert. Radiology,  
Senior lecturer University of Giessen, Germany, Veterinary Faculty, Department of Radiology  
Nele.Eley@sonopath.com

**REFERRING VET**

Dr. Luna

**INVOICE**

56857

**DATE**

2-17-23