



## PATIENT

Puszek Szynczak

## SPECIES

Canine

## BREED

Maltese

## SEX

Male Neutered

## AGE

11/10

## WEIGHT

8.2kg

## INTERPRETED BY

Nele Eley (Ondreka),  
DVM Dr. med. vet.,  
DipECVDI

## IMAGING PERFORMED BY

NA

## HOSPITAL NAME

Green Dog Dental and  
Wellness

## REFERRING VET

Dr Habawel

## INVOICE

73792

## DATE

2-16-26

## PRESENTING CLINICAL SIGNS

- Chief complaint: instability and collapse when attempting to urinate as well as when playing with toys at home, on hardwood floors.
- P has a hx of Left tibial tuberosity fracture (2018), Hx Right TPLO (2020), bilateral CCL tear (2020).
- P had an extraction procedure and oral mass biopsy done on 1-30-26

Abnormal PE/Chem/CBC/UA Results: - Sensitivity noted when manipulating left and right stifles. Comfortable upon movement of hips. Slipping in turns when lameness exam was performed. - Mild elevation in ALT(152), MPV (14.8), decreased MCH (21.1)- all other values within normal limits.

## RADIOGRAPHIC STUDY OF THE STIFLES

Mediolateral and craniocaudal views of both stifles totaling 6 images available for review.

## RADIOGRAPHIC FINDINGS

### Right Stifle

Post-operative changes consistent with a healed TPLO procedure are seen. The implants are intact and appropriately positioned with no evidence of loosening or failure. No abnormal soft tissue swelling is seen. The osteotomy is completely healed with smooth cortical remodeling.

Moderate osteoarthritic changes characterized by periarticular osteophyte formation involving the patella, trochlear ridges, tibial plateau, and distal femur are seen.

No significant joint effusion or aggressive osseous change is identified.

The patella is normally positioned within the trochlear groove without evidence of luxation.

### Left Stifle

Changes consistent with healed tibial tuberosity transposition with complete osseous union and remodeling are seen. The implants are intact and in normal position.

Mild osteoarthritic changes with small periarticular osteophytes are seen.

Joint alignment is normal.

Patella is seated within the trochlear groove.

## RADIOGRAPHIC DIAGNOSIS

- Healed right TPLO with expected post-operative appearance and moderate osteoarthritis of the right stifle joint.
- Healed left tibial tuberosity transposition with mild left stifle osteoarthritis.

## INTERPRETATION OF FINDINGS & FURTHER RECOMMENDATIONS

There are no radiographic signs of acute orthopedic pathology to explain the episodic collapse. The observed degenerative joint disease is chronic and expected given the patient's surgical history and age. The degree of osteoarthrosis may cause stiffness or intermittent lameness but is unlikely to result in sudden collapse or marked instability of the hind limbs. Therefore, other causes such as neurologic,



## PATIENT

Puszek Szynczak

## SPECIES

Canine

## BREED

Maltese

## SEX

Male Neutered

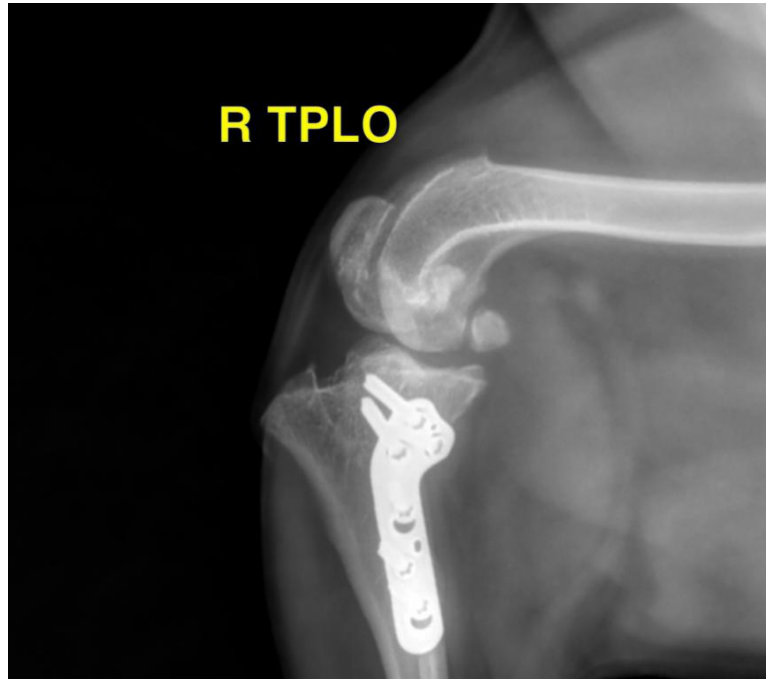
## AGE

11/10

## WEIGHT

8.2kg

lumbosacral, metabolic, or systemic may be considered if clinical signs persist.



## INTERPRETED BY

Nele Eley (Ondreka),  
DVM Dr. med. vet.,  
DipECVDI

The information and recommendations provided are based on the images presented by the referring veterinarian. No evaluation can be communicated regarding pathology that was not visible in the image/video clips provided.

## IMAGING PERFORMED BY

NA

Thank you for this referral. If the clinical or image interpretation does not parallel your findings or if I can be of any further assistance please contact me.

## HOSPITAL NAME

Green Dog Dental and  
Wellness

**Nele Eley (Ondreka)**, DVM, Dr. med. vet., DipECVDI  
European Specialist in Veterinary Diagnostic Imaging, Cert. Radiology,  
Senior lecturer University of Giessen/Germany, Veterinary Faculty, Department of Radiology.  
[info@sonopath.com](mailto:info@sonopath.com)

## REFERRING VET

Dr Habawel

## INVOICE

73792

## DATE

2-16-26