



## PATIENT

Lantern Tressel

## SPECIES

Canine

## BREED

Mixed

## SEX

Male Neutered

## AGE

4Y, 15D

## WEIGHT

60.0

## INTERPRETED BY

Nele Eley (Ondreka),  
DVM Dr. med. vet.,  
DipECVDI

## IMAGING PERFORMED BY

DTLAvets

## HOSPITAL NAME

DTLAvets

## REFERRING VET

Dr. Fuller

## INVOICE

73759

## DATE

2-16-26

## PRESENTING CLINICAL SIGNS

Lantern presents today for limping on LHL; P was at the dog park on Friday and tried to chase after another dog. O held the leash tight and thinks that P may have pulled/strained a muscle. P favoring leg, occasionally holding it up.

## RADIOGRAPHIC STUDY OF THE LEFT STIFLE

Mediolateral and craniocaudal views are available for review.

## RADIOGRAPHIC FINDINGS

Moderate articular swelling of the left stifle joint is noted representing synovial / capsular thickening and/or effusion. Osteophyte formation is noted along the femoral condyles, tibial plateau, and fabellae suggestive of early degenerative joint changes. There is cranial thrust of the tibia consistent with cranial cruciate ligament instability.

## RADIOGRAPHIC DIAGNOSIS

- Radiographic presence of cranial cruciate ligament insufficiency represented by cranial tibial thrust and moderate degenerative changes of the left stifle.

## INTERPRETATION OF FINDINGS & FURTHER RECOMMENDATIONS

The clinical signs and radiographic findings are consistent with cranial cruciate ligament injury of the left stifle. Mild to moderate concurrent osteoarthritic changes are seen. Consider orthopedic consultation for treatment options such as surgical stabilization with TPLO, TTA, or other appropriate techniques.



## PATIENT

Lantern Tressel

## SPECIES

Canine

## BREED

Mixed

## SEX

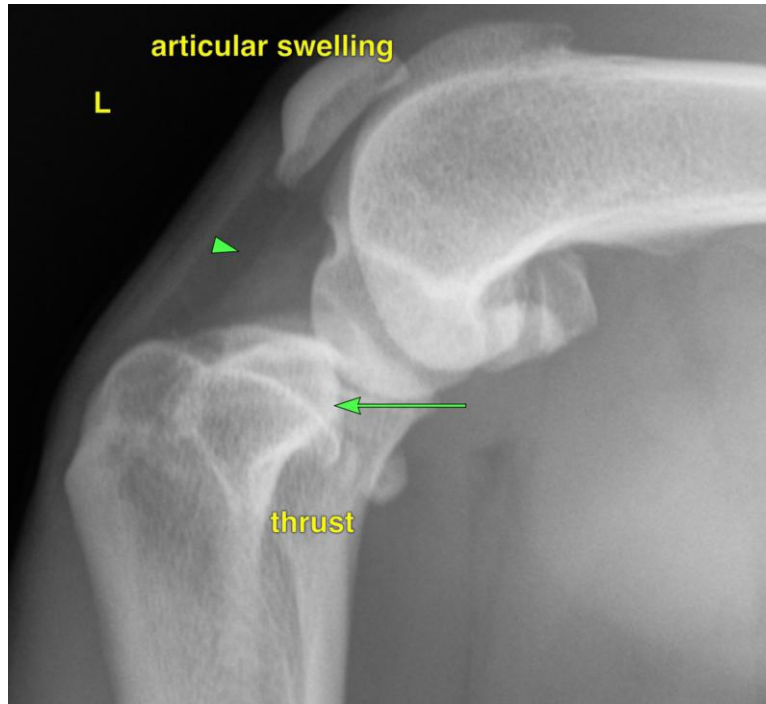
Male Neutered

## AGE

4Y, 15D

## WEIGHT

60.0



## INTERPRETED BY

Nele Eley (Ondreka),  
DVM Dr. med. vet.,  
DipECVDI

The information and recommendations provided are based on the images presented by the referring veterinarian. No evaluation can be communicated regarding pathology that was not visible in the image/video clips provided.

Thank you for this referral. If the clinical or image interpretation does not parallel your findings or if I can be of any further assistance please contact me.

## IMAGING PERFORMED BY

DTLAvets

**Nele Eley (Ondreka)**, DVM, Dr. med. vet., DipECVDI  
European Specialist in Veterinary Diagnostic Imaging, Cert. Radiology,  
Senior lecturer University of Giessen/Germany, Veterinary Faculty, Department of Radiology.  
[info@sonopath.com](mailto:info@sonopath.com)

## HOSPITAL NAME

DTLAvets

## REFERRING VET

Dr. Fuller

## INVOICE

73759

## DATE

2-16-26