



PATIENT PRESENTING CLINICAL SIGNS

PATIENT
Stella Rossi

SPECIES
Canine

BREED
Chi

SEX
FS

AGE
17 Years

REFERRING VET
Moffitt

INVOICE
56833

DATE
2-16-23

P presented with left preorbital swelling on 6/20/2022. Started oral steroids and saw improvement but abscess presented in the same area (left periorbital region) weeks after discontinuation. Treated with steroids and antibiotic this time around. Responsive to ABC/steroid tx. Suspicious of possible tooth abscess. Dental done on 12/1/2022, small retained root fragments were noted from RT upper quadrant and both lower quadrants. No obvious cause of left sided abscess found during time of dental. Small hairline fracture of maxillary bone near nasal cavity appreciated in dental rads : No obvious sign of oronasal fistula upon exam. P presented with unresolved abscess again on 2/6.

COMPUTED TOMOGRAPHIC STUDY OF THE HEAD

Plain and post contrast studies in soft tissue and bone windows available for review.

COMPUTED TOMOGRAPHIC FINDINGS

The patient has a history of left periorbital abscess and dental revisions.

All tooth elements are removed.

An incomplete fracture of the left caudal maxilla is seen level with the base of the rostral aspect of the zygomatic arch and rostral aspect of the left infraorbital canal. A small sclerotic 1.5mm sized sharply delineated fragment is seen level with the incomplete fracture / fissure. Regional soft tissue swelling with increased contrast enhancement and no evidence of cavitation is noted. The surrounding bones present smoothly contoured and regular trabecular and cortical layering.

Paucity of turbinates is seen within the rostral third of the right nasal cavity with no concurrent signs of rhinitis.

Mild medullary sclerosis of the left mandibular body with no evidence of aggressive osteolytic or osteoproliferative changes is seen.

The eyes and intraorbital soft tissues present within normal limits.

The regional lymph nodes present within normal limits.

No evidence of a dental-nasal fistula is seen.

COMPUTED TOMOGRAPHIC DIAGNOSIS

- Incomplete fracture/fissure of the left maxilla at the base on the zygomatic arch and infraorbital canal with small isolated bone fragment and regional soft tissue swelling.

INTERPRETATION OF THE FINDINGS & FURTHER RECOMMENDATIONS

The CT study confirms presence of a fissure/incomplete fracture of the left maxilla at the base of the zygomatic arch with regional soft tissue swelling which may represent regional inflammation or organizing hematoma, and less likely septic cellulitis. The small isolated bone fragment may carry the potential to develop in a sequestrum, however, it is very small and may be undergoing bone resorption as well. Note the regional involvement of the rostral margin of the left



PATIENT

Stella Rossi

infraorbital canal which may involve the infraorbital nerve as well. At this time, the soft tissue changes do not present evidence of cavitation, rim enhancement, or other typical abscess patterns.

No regional lymphadenitis is noted.

SPECIES

Canine

BREED

Chi

SEX

FS

AGE

17 Years

INTERPRETED BY

Nele Eley, DVM
Dr. med. Vet. DipECVDI

HOSPITAL NAME

Green Dog Dental and
Wellness

REFERRING VET

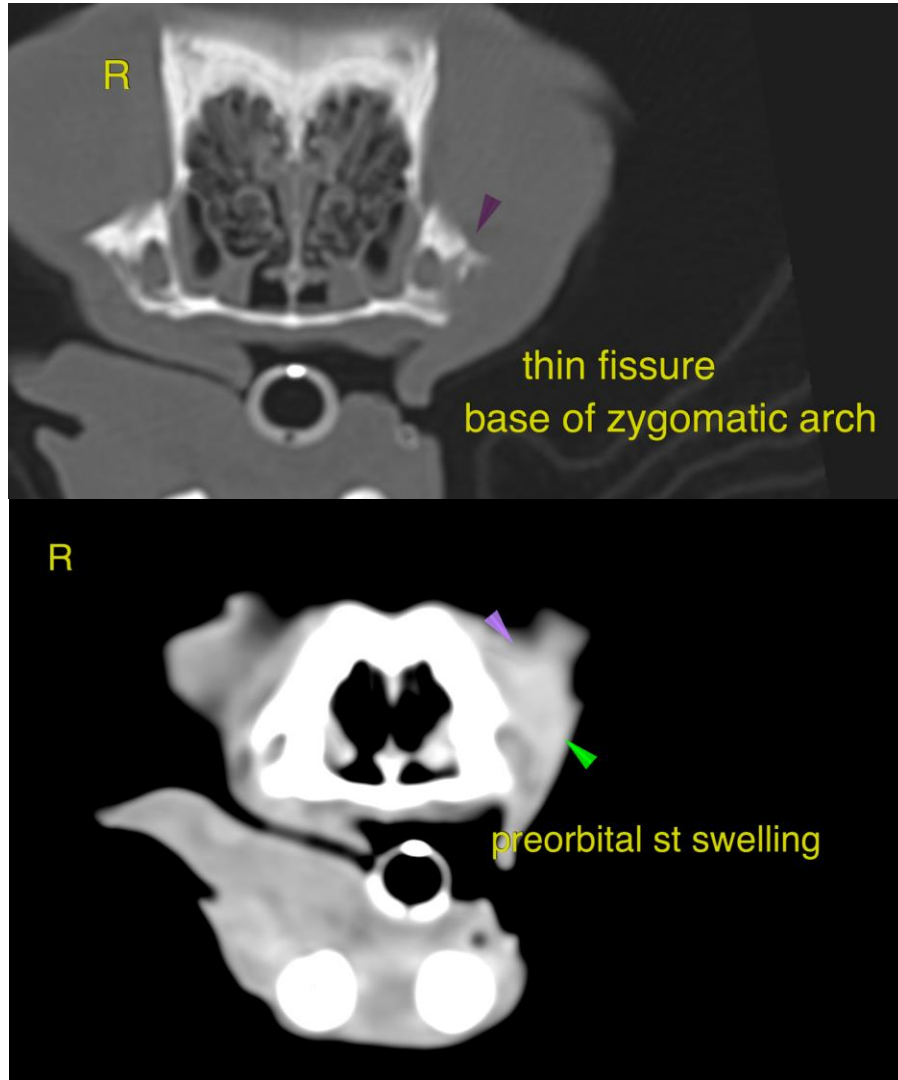
Moffitt

INVOICE

56833

DATE

2-16-23





PATIENT

Stella Rossi

SPECIES

Canine

BREED

Chi

SEX

FS

AGE

17 Years

INTERPRETED BY

Nele Eley, DVM
Dr. med. Vet. DipECVDI

HOSPITAL NAME

Green Dog Dental and
Wellness

REFERRING VET

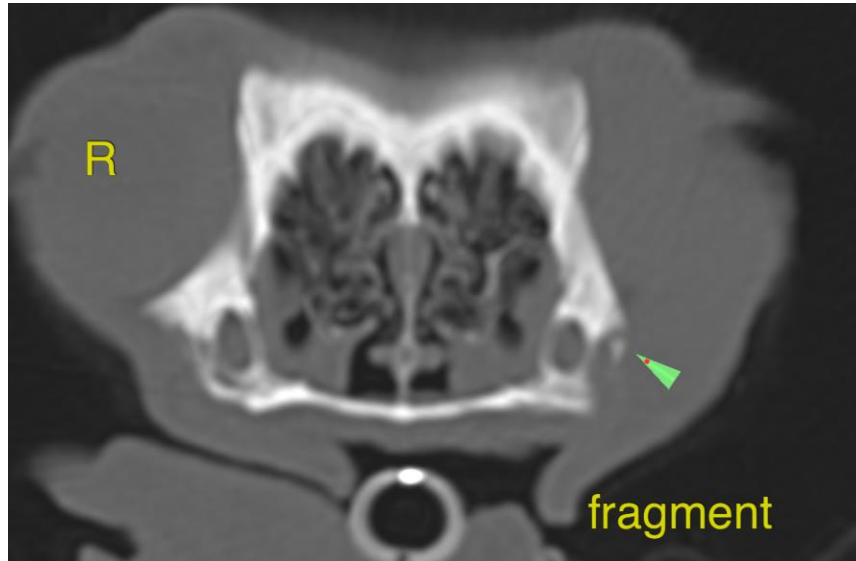
Moffitt

INVOICE

56833

DATE

2-16-23



The information and recommendations provided are based on the images presented by the referring veterinarian/sonographer. No evaluation can be communicated regarding pathology that was not visible in the image/video clips provided.

Thank you for this referral. If the clinical or image interpretation does not parallel your findings or if I can be of any further assistance please contact me.

Nele Eley, DVM, Dr. med. vet., DipECVDI
European Specialist in Veterinary Diagnostic Imaging, Cert. Radiology,
Senior lecturer University of Giessen, Germany, Veterinary Faculty, Department of Radiology
Nele.Eley@sonopath.com