



PATIENT

Lexi Makkar

PRESENTING CLINICAL SIGNS

slightly limping left hind leg for 5 days.

SPECIES

Canine

RADIOGRAPHIC STUDY OF THE PRESUMED LEFT STIFLE & PELVIS

Mediolateral view of one stifle, side marker not available, and ventrodorsal and lateral views of the pelvis totaling 3 images available for review in jpeg format.

BREED

Boxer X Mastiff

RADIOGRAPHIC FINDINGS

Stifle

The radiographic presentation of the stifle is within normal limits. No evidence of articular swelling, tibial thrust, subchondral bone defects, or osteoarthritis is seen. there is no evidence of aggressive bone disease.

SEX

Female Spayed

Pelvis

The coxofemoral joints present within age related normal limits. Femoral head coverage is adequate. The joint spaces are narrow and even. There are no signs of osteoarthritis.

AGE

9 Years

An asymmetric lumbosacral transitional vertebra is seen with incomplete separation of the 1st sacral vertebra from the remainder of the sacrum and asymmetric lateral parts of the sacrum.

INTERPRETED BY

Nele Eley, DVM
Dr. med. Vet. DipECVDI

The patient appears to be mildly obese.

RADIOGRAPHIC DIAGNOSIS

- Asymmetric lumbosacral transitional vertebra.
- Normal radiographic presentation of the pelvis and stifle joint.

HOSPITAL NAME

Ehab Hanna

INTERPRETATION OF THE FINDINGS & FURTHER RECOMMENDATIONS

The radiographic study reveals no evidence of stifle arthropathy. The coxofemoral joints present within normal limits. No evidence of aggressive bone disease is seen.

REFERRING VET

Dr. Mari

There is a congenital asymmetric lumbosacral transitional vertebra which may alter the biomechanics of the lumbosacral junction and predispose to early degeneration of the lumbosacral intervertebral disc and degenerative lumbosacral stenosis. Clinical correlation is required.

INVOICE

56815

DATE

2-16-23



PATIENT

Lexi Makkar

SPECIES

Canine

BREED

Boxer X Mastiff

SEX

Female Spayed

AGE

9 Years

INTERPRETED BY

Nele Eley, DVM
Dr. med. Vet. DipECVDI

HOSPITAL NAME

Ehab Hanna

REFERRING VET

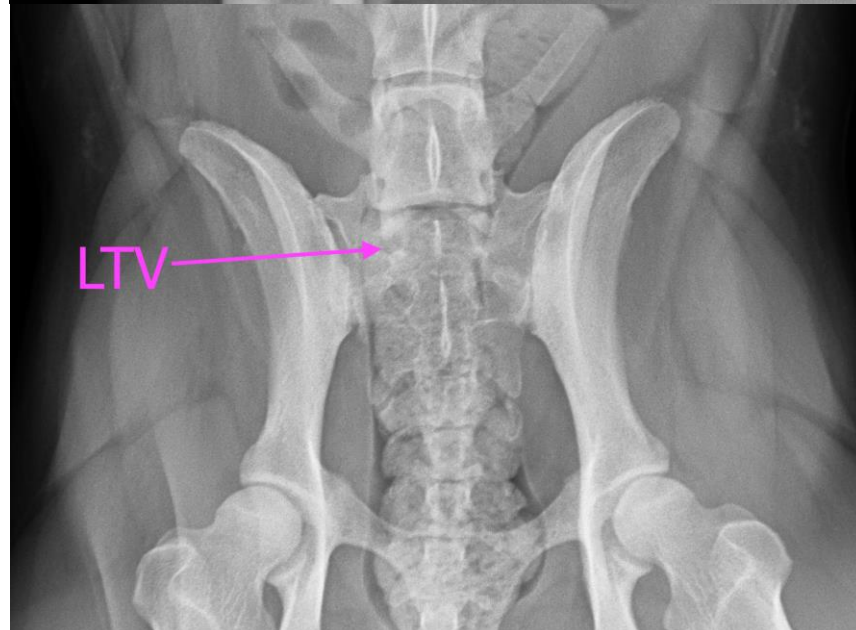
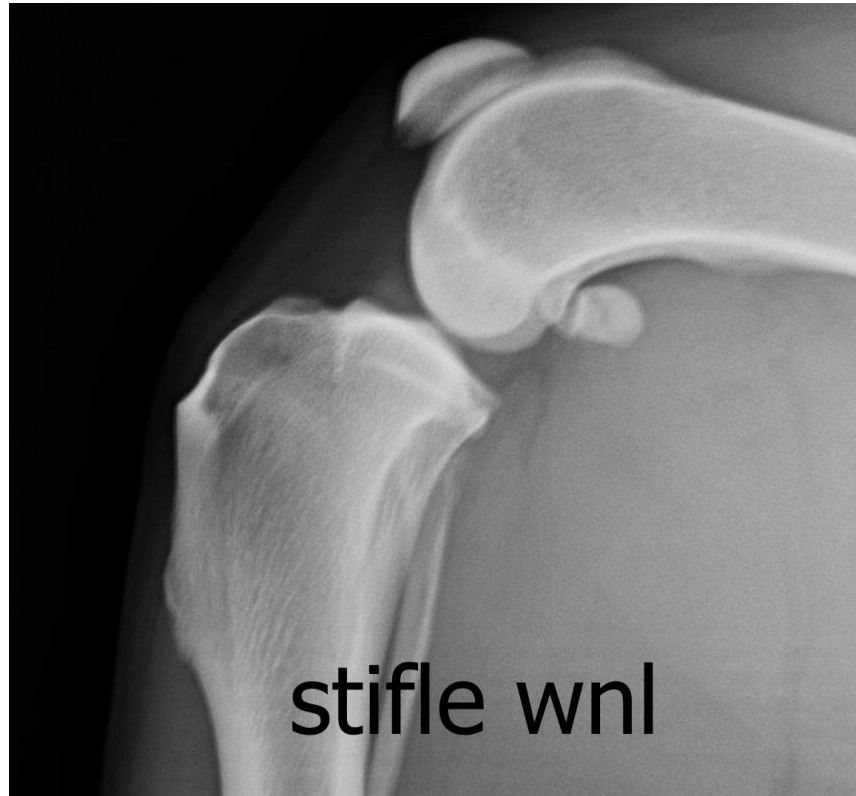Dr. Mari

INVOICE

56815

DATE

2-16-23





PATIENT

Lexi Makkar

The information and recommendations provided are based on the images presented by the referring veterinarian/sonographer. No evaluation can be communicated regarding pathology that was not visible in the image/video clips provided.

Thank you for this referral. If the clinical or image interpretation does not parallel your findings or if I can be of any further assistance please contact me.

SPECIES

Canine

Nele Eley, DVM, Dr. med. vet., DipECVDI
European Specialist in Veterinary Diagnostic Imaging, Cert. Radiology,
Senior lecturer University of Giessen, Germany, Veterinary Faculty, Department of Radiology
Nele.Eley@sonopath.com

BREED

Boxer X Mastiff

SEX

Female Spayed

AGE

9 Years

INTERPRETED BY

Nele Eley, DVM
Dr. med. Vet. DipECVDI

HOSPITAL NAME

Ehab Hanna

REFERRING VET

Dr. Mari

INVOICE

56815

DATE

2-16-23