



PATIENT

Coco Auten

PRESENTING CLINICAL SIGNS

Patient presented as referral for CT for possible left sided retropharyngeal mass found on radiographs. Pet has been coughing and having difficulty keeping food down Sending out full senior BW today including thyroid

SPECIES

Canine

COMPUTED TOMOGRAPHIC STUDY OF THE HEAD & NECK

Plain and post contrast studies of head and neck available for review.

BREED

Springer Spaniel

COMPUTED TOMOGRAPHIC FINDINGS

An irregular shaped ill-defined 4.6 x 3.6 cm sized ovoid soft tissue mass is seen in the left retropharyngeal area. The mass is lateral and caudal to the larynx and appears to be continuous with as well as contained within the esophageal wall. Focal mineralization and strong nonuniform contrast enhancement with multiple intralesional cavitations are seen. The esophagus is mildly dilated with fluid and gas caudal to the mass.

SEX

FS

Both lobes of the thyroid gland can be seen separate from the mass and present within normal limits.

AGE

11 Years

The medial retropharyngeal and submandibular lymph nodes present within normal limits as well.

COMPUTED TOMOGRAPHIC DIAGNOSIS

- Large upper cervical esophageal mass meeting neoplastic criteria.

INTERPRETED BY

Nele Eley, DVM
Dr. med. Vet. DipECVDI

INTERPRETATION OF THE FINDINGS & FURTHER RECOMMENDATIONS

The CT study reveals a soft tissue mass meeting neoplastic criteria which appears to be originating from and contained within the upper cervical esophagus. Differential diagnosis includes esophageal squamous cell carcinoma, leiomyosarcoma, fibrosarcoma, or lymphosarcoma. Leiomyoma or other benign neoplasia is thought less likely based on the CT presentation. Final diagnosis will require sampling. Samples could be obtained under ultrasonographic guidance or via endoscopy.

HOSPITAL NAME

Boca Park Animal
Hospital

REFERRING VET

Dr. Corinna Gorgon

INVOICE

56807

DATE

2-16-23



PATIENT

Coco Auten

SPECIES

Canine

BREED

Springer Spaniel

SEX

FS

AGE

11 Years

INTERPRETED BY

Nele Eley, DVM
Dr. med. Vet. DipECVDI

HOSPITAL NAME

Boca Park Animal
Hospital

REFERRING VET

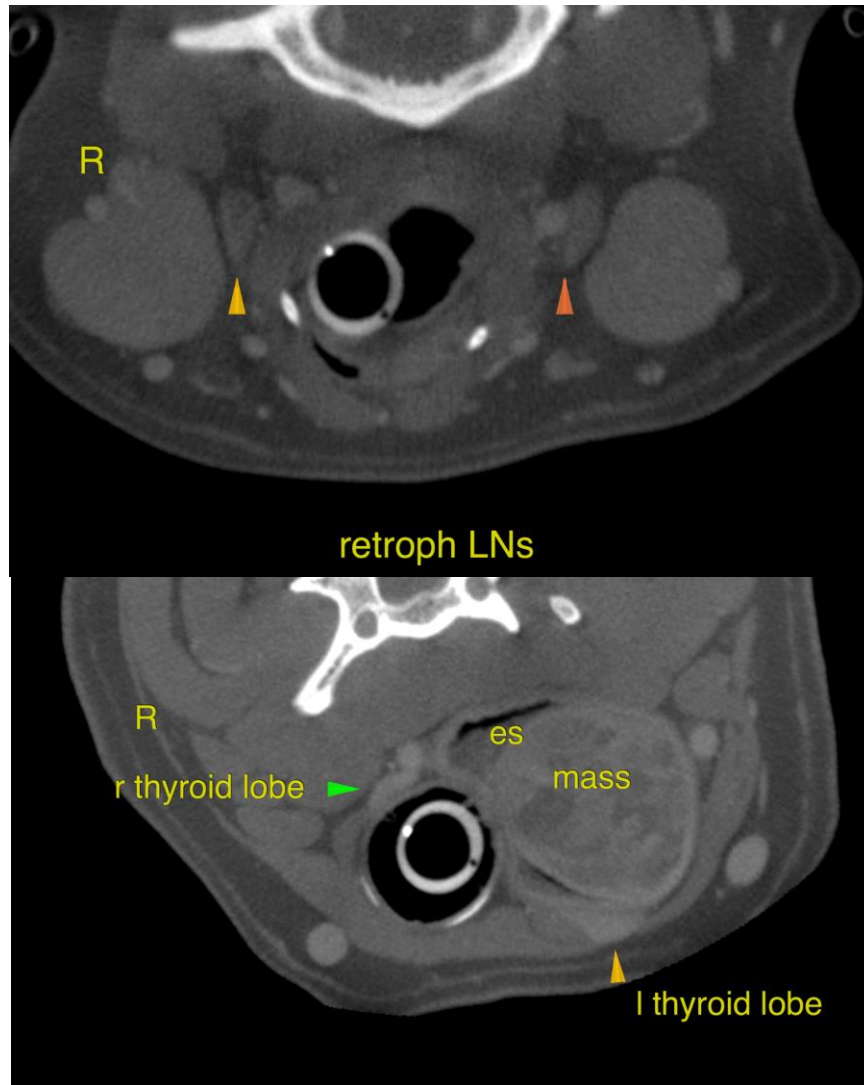
Dr. Corinna Gorgon

INVOICE

56807

DATE

2-16-23





PATIENT

Coco Auten

SPECIES

Canine

BREED

Springer Spaniel

SEX

FS

AGE

11 Years

INTERPRETED BY

Nele Eley, DVM
Dr. med. Vet. DipECVDI

HOSPITAL NAME

Boca Park Animal
Hospital

REFERRING VET

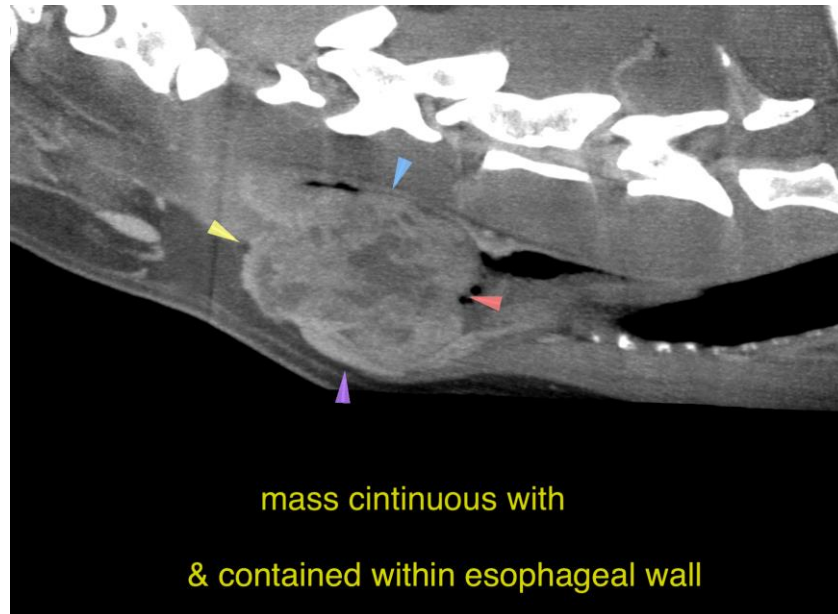
Dr. Corinna Gorgon

INVOICE

56807

DATE

2-16-23



The information and recommendations provided are based on the images presented by the referring veterinarian/sonographer. No evaluation can be communicated regarding pathology that was not visible in the image/video clips provided.

Thank you for this referral. If the clinical or image interpretation does not parallel your findings or if I can be of any further assistance please contact me.

Nele Eley, DVM, Dr. med. vet., DipECVDI
European Specialist in Veterinary Diagnostic Imaging, Cert. Radiology,
Senior lecturer University of Giessen, Germany, Veterinary Faculty, Department of Radiology
Nele.Eley@sonopath.com