



PATIENT

Pip Sydrych

SPECIES

Canine

BREED

Collie

SEX

FN

AGE

12

WEIGHT

25.5

INTERPRETED BY

Nele Eley (Ondreka),
DVM Dr. med. vet.,
DipECVDI

IMAGING PERFORMED BY

Eamon

HOSPITAL NAME

Belconnen Veterinary
Centre

REFERRING VET

Eamon

INVOICE

73760

DATE

2-15-26

PRESENTING CLINICAL SIGNS

- weight loss
- reduced appetite
- vomiting bile post exercise
- thick gastric wall on u/s (10-17mm)

Abnormal PE/Chem/CBC/UA Results: cbc wl chem wl

COMPUTED TOMOGRAPHIC STUDY OF THE ABDOMEN

Plain and post contrast studies are available for review.

COMPUTED TOMOGRAPHIC FINDINGS

The serosal fat presents normal attenuation behavior. There is no evidence of peritoneal effusion or peritonitis.

Both kidneys present within normal limits for size, shape and organ architecture. After contrast administration, a bilaterally symmetric and uniform nephro- and pyelogram is noted.

The ovaries and uterus present unremarkable.

The adrenal glands are within normal limits for size, shape and organ architecture.

Hyperenhancing splenic nodules are seen.

The liver presents with normal shape, even surface, uniformly attenuating parenchyma and homogeneous contrast enhancement, unremarkable.

Mildly diffuse pancreatic enlargement with slightly decreased definition of surrounding fat planes is seen.

Diffuse generalized wall thickening of the stomach is seen with obscured wall layering and wall thickness ranging between 8-12mm. The wall thickening is accentuated in the region of the gastric fundus and pyloric antrum. Thickening is circumferential and uniform.

Mild surrounding fat stranding within the epigastric and portal hilus region is seen.

Multiple mildly enlarged epigastric lymph nodes are noted.

COMPUTED TOMOGRAPHIC DIAGNOSIS

- Diffuse gastric wall thickening with regional lymphadenopathy and fat stranding.
- Mild pancreatic enlargement suggestive of concurrent mild pancreatitis.
- Incidental splenic nodular hyperplasia.

INTERPRETATION OF FINDINGS & FURTHER RECOMMENDATIONS

The CT study reveals diffuse gastric wall thickening with mild regional lymphadenopathy. The findings are most consistent with infiltrative gastric disease rather than a focal neoplasm. Differential diagnoses include gastric lymphoma and severe hypertrophic or other gastritis. Endoscopic evaluation with multiple deep gastric biopsies or full thickness surgical biopsies could be considered. Histopathology is



PATIENT

Pip Sydrych

SPECIES

Canine

BREED

Collie

SEX

FN

AGE

12

WEIGHT

25.5

INTERPRETED BY

Nele Eley (Ondreka),
DVM Dr. med. vet.,
DipECVDI

IMAGING PERFORMED BY

Eamon

HOSPITAL NAME

Belconnen Veterinary
Centre

REFERRING VET

Eamon

INVOICE

73760

DATE

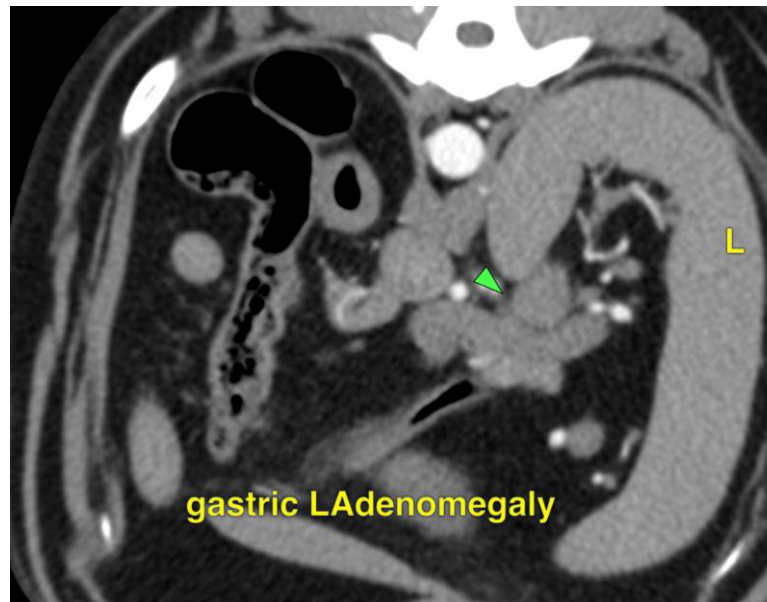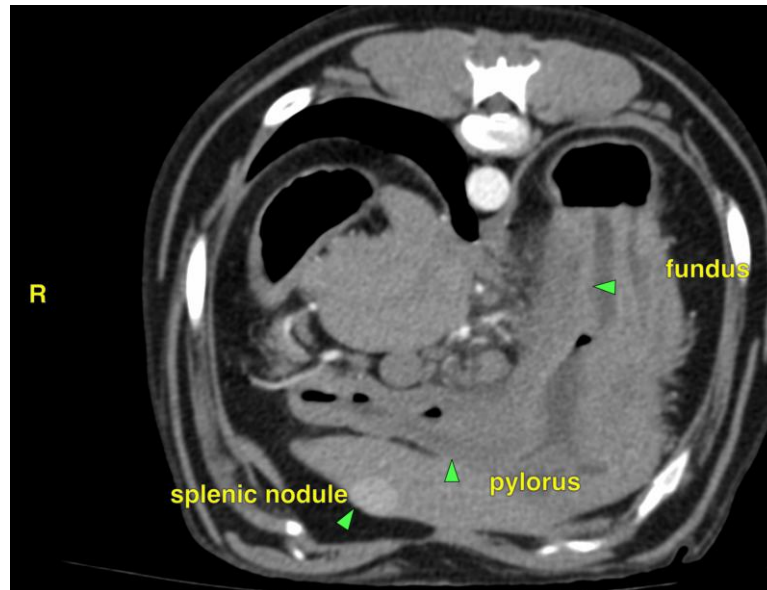
2-15-26

essential to differentiate lymphoma vs severe inflammatory disease.

Consider pancreatic lipase testing.

The splenic nodules are likely benign representing nodular hyperplasia. Neoplasia cannot be ruled out entirely but is considered unlikely. Further ultrasonographic monitoring could be considered.

The regional lymphadenopathy is most concerning for reactive change even though neoplastic/lymphomatous infiltrate cannot be ruled out entirely. Ultrasound guided or surgical sampling could be considered for further definition.





PATIENT

Pip Sydrych

SPECIES

Canine

BREED

Collie

SEX

FN

AGE

12

WEIGHT

25.5

INTERPRETED BY

Nele Eley (Ondreka),
DVM Dr. med. vet.,
DipECVDI

IMAGING PERFORMED BY

Eamon

HOSPITAL NAME

Belconnen Veterinary
Centre

REFERRING VET

Eamon

INVOICE

73760

DATE

2-15-26

The information and recommendations provided are based on the images presented by the referring veterinarian. No evaluation can be communicated regarding pathology that was not visible in the image/video clips provided.

Thank you for this referral. If the clinical or image interpretation does not parallel your findings or if I can be of any further assistance please contact me.

Nele Eley (Ondreka), DVM, Dr. med. vet., DipECVDI

European Specialist in Veterinary Diagnostic Imaging, Cert. Radiology,

Senior lecturer University of Giessen/Germany, Veterinary Faculty, Department of Radiology.

info@sonopath.com