



PATIENT

Jackson Prather

PRESENTING CLINICAL SIGNS

Coughing started January 10th, dry hacking cough that is worse in the morning. no cough with tracheal or laryngeal palpation but did have mild harsh hack/huffing when he pulled on the leash. Patient has been on Doxycycline, guaifenesin, temeral-p, hydrocodone.

SPECIES

Canine

RADIOGRAPHIC STUDY OF THE THORAX

Right/left lateral and ventrodorsal views of the thorax and lateral view of the neck totaling 4 images available for review.

BREED

Boxer

RADIOGRAPHIC FINDINGS

Bilateral shoulder osteoarthritis is noted.

SEX

Neutered Male

The vertebral heart score is 11 which is within the reference range in this breed. No significant chamber enlargement of the heart is seen.

AGE

6 Years, 8 Months

The degree of pulmonary inflation is moderate. A moderate generalized bronchointerstitial lung pattern is noted and evenly distributed throughout the lung.

Mild redundancy of the dorsal tracheal ligament is seen in the caudal cervical trachea on one lateral view of the thorax and a lateral view of the neck.

No evidence of abnormal mediastinal widening is noted.

INTERPRETED BY

Nele Eley, DVM
Dr. med. Vet. DipECVDI

Multiple mild to moderate spondyloses are seen within the thoracic and cranial lumbar spine.

The liver and stomach present within expected limits.

HOSPITAL NAME

All Creatures Animal
Hospital of South Hill,
Inc.

RADIOGRAPHIC DIAGNOSIS

- Moderate generalized bronchointerstitial lung pattern.
- Redundancy of the dorsal tracheal ligament.
- Multiple spondyloses.

INTERPRETATION OF THE FINDINGS & FURTHER RECOMMENDATIONS

REFERRING VET

Dr. Diana Land

The radiographic study reveals a moderate generalized bronchointerstitial lung pattern. Differential diagnosis includes eosinophilic / allergic bronchopneumopathy and infectious bronchitis including viral, bacterial, and parasitic. Lung worm testing and airway endoscopy with airway sampling are recommended for further definition since the patient appears to be refractory to various medications.

INVOICE

56754

Redundancy of the dorsal tracheal ligament can be an incidental finding. However, it may indicate a predisposition for dynamic tracheal disease. Clinical correlation required.

DATE

2-15-23



PATIENT

Jackson Prather

SPECIES

Canine

BREED

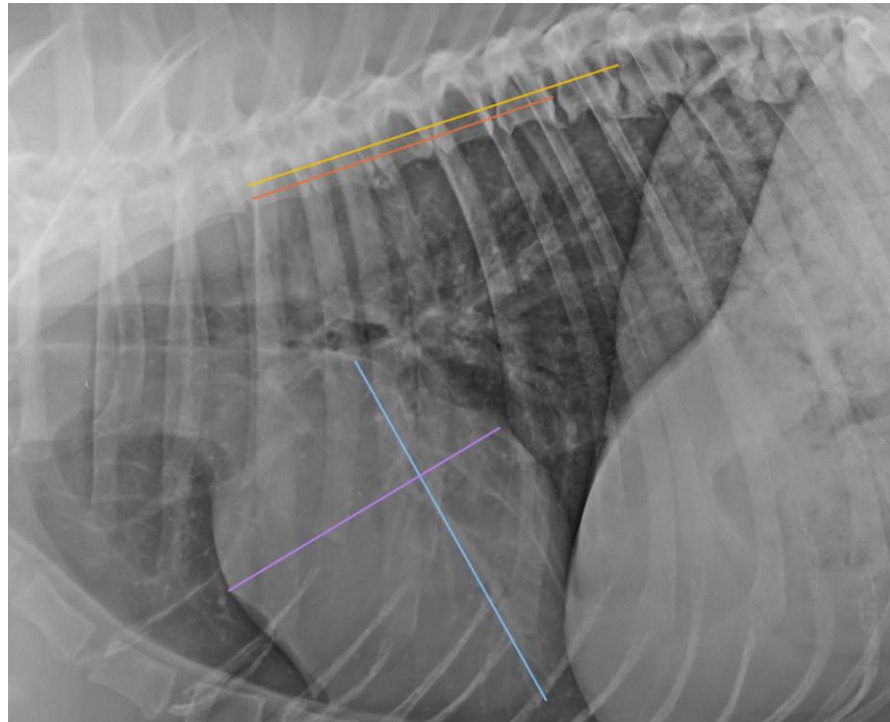
Boxer

SEX

Neutered Male

AGE

6 Years, 8 Months



INTERPRETED BY

Nele Eley, DVM
Dr. med. Vet. DipECVDI

The information and recommendations provided are based on the images presented by the referring veterinarian/sonographer. No evaluation can be communicated regarding pathology that was not visible in the image/video clips provided.

HOSPITAL NAME

All Creatures Animal
Hospital of South Hill,
Inc.

Thank you for this referral. If the clinical or image interpretation does not parallel your findings or if I can be of any further assistance please contact me.

Nele Eley, DVM, Dr. med. vet., DipECVDI
European Specialist in Veterinary Diagnostic Imaging, Cert. Radiology,
Senior lecturer University of Giessen, Germany, Veterinary Faculty, Department of Radiology
Nele.Eley@sonopath.com

REFERRING VET

Dr. Diana Land

INVOICE

56754

DATE

2-15-23