



PATIENT

Dice Valle

PRESENTING CLINICAL SIGNS

Pt presented for vomiting 2-3x a week. Pt also always seems hungry. The last 2 days, pt has had diarrhea. PE: hard mass palpated in abd. BW/UA pending.

SPECIES

Feline

RADIOGRAPHIC STUDY OF THE ABDOMEN

Right/left lateral and ventrodorsal views of the abdomen totaling 3 images available for review.

BREED

DSH

RADIOGRAPHIC FINDINGS

An approximately 6 x 4 cm sized ovoid soft tissue opaque mass effect is seen in the mid abdomen. The mass effect appears to be in a central mesenteric position. The small and large intestine are deviated to the periphery of this mass effect.

SEX

NM

Mild subjective small intestinal wall thickening is noted even though this assessment limited radiographically.

AGE

5.5 Years

The liver, spleen, and kidneys present within normal limits.

The abdominal serosal detail is maintained.

RADIOGRAPHIC DIAGNOSIS

- Suspect mesenteric soft tissue mass within the mid abdomen.

INTERPRETED BY

Nele Eley, DVM
Dr. med. Vet. DipECVDI

INTERPRETATION OF THE FINDINGS & FURTHER RECOMMENDATIONS

The radiographic study suggests presence of a soft tissue mass of mesenteric origin in the mid abdomen. The mass measures approximately 6 x 4 cm. Mesenteric lymphadenomegaly is considered a primary differential diagnosis. Other mesenteric and intestinal mass are potential but less likely differential diagnoses. Note the potential for diffuse small intestinal wall thickening which is suggested by the radiographic presentation but requires further verification by means of abdominal ultrasound. Full abdominal ultrasound is recommended in order to further define the origin and character of the mesenteric soft tissue mass and to rule out small intestinal involvement such as wall thickening as well as other associated abdominal pathology.

HOSPITAL NAME

The Pet Hospital of
Stratford

REFERRING VET

Dr. Giuliani

INVOICE

56768

DATE

2-15-23



PATIENT

Dice Valle

SPECIES

Feline

BREED

DSH

SEX

NM

AGE

5.5 Years

INTERPRETED BY

Nele Eley, DVM
Dr. med. Vet. DipECVDI

HOSPITAL NAME

The Pet Hospital of
Stratford

REFERRING VET

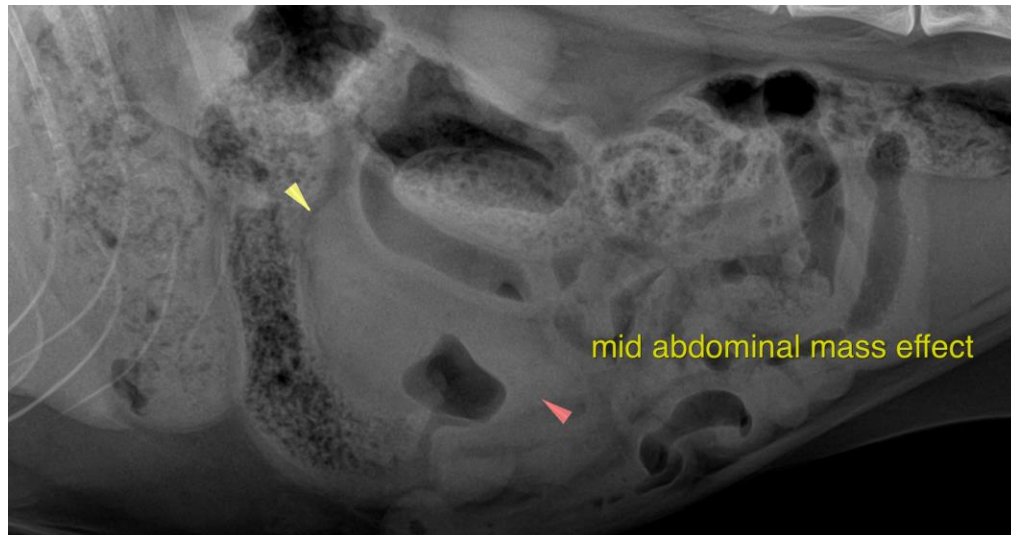
Dr. Giuliani

INVOICE

56768

DATE

2-15-23



The information and recommendations provided are based on the images presented by the referring veterinarian/sonographer. No evaluation can be communicated regarding pathology that was not visible in the image/video clips provided.

Thank you for this referral. If the clinical or image interpretation does not parallel your findings or if I can be of any further assistance please contact me.

Nele Eley, DVM, Dr. med. vet., DipECVDI
European Specialist in Veterinary Diagnostic Imaging, Cert. Radiology,
Senior lecturer University of Giessen, Germany, Veterinary Faculty, Department of Radiology
Nele.Eley@sonopath.com