



**PATIENT PRESENTING CLINICAL SIGNS**

Luna Resto P presents for gagging. O states that yesterday when he got home, P was chewing on a stick (there were multiple little pieces everywhere). No vomiting, no diarrhea. No contact with other dogs (daycare or otherwise). P is eating/drinking with no difficulties and going to the bathroom normally. PE: no visible fb if mouth or throat, mildly enlarged, red tonsil on rt side

**SPECIES**

Canine

**RADIOGRAPHIC STUDY OF THE THORAX & ABDOMEN**

Lateral and orthogonal views of the neck, thorax, and abdomen totaling 10 images available for review.

**BREED**

GSD

**RADIOGRAPHIC FINDINGS**

**Neck**

**SEX**

Female

The nasopharyngeal and laryngopharyngeal gas columns present within normal limits. The soft palate and epiglottis present within normal limits. Gas is seen within the laryngeal ventricles.

The hyoid bone and laryngeal cartilages present within normal limits.

**AGE**

1.5 Years

Course and width of the trachea are considered within normal limits.

A mild amount of gas is seen within the thoracic esophagus cranial to, level with, and caudal to the cardiac silhouette cranial to the lower esophageal sphincter.

**INTERPRETED BY**

Nele Eley, DVM  
Dr. med. Vet. DipECVDI

Another lateral view obtained 1 minute later does not show esophageal aerophagia again.

**Thorax**

The lungs are moderately inflated and present within expected limits.

The cardiac silhouette and mediastinum present within normal limits.

The thoracic boundaries present within normal limits.

**HOSPITAL NAME**

The Pet Hospital of  
Stratford

**Abdomen**

**REFERRING VET**

Dr Giuliani

The abdominal serosal detail is maintained.

Mild generalized splenomegaly is seen.

**INVOICE**

56740

The stomach is postprandial.

The small intestinal loops are evenly distributed throughout the mid abdomen with no evidence of abnormal dilation, plication, or radiopaque foreign material.

**DATE**

2-14-23

The colon contains a moderate amount of inspissated fecal matter.



**PATIENT**

Luna Resto

**RADIOGRAPHIC DIAGNOSIS**

- Transient esophageal aerophagia
- No evidence of tracheal or esophageal abnormality.
- Normal radiographic presentation of the thorax and abdomen.

**SPECIES**

Canine

**INTERPRETATION OF THE FINDINGS & FURTHER RECOMMENDATIONS**

The radiographic findings of the neck, thorax, and abdomen are within normal limits. There is no evidence of perforating injury of the larynx, trachea, or esophagus. No radiopaque foreign material is seen. The thoracic and abdominal structures present within normal limits as well.

**BREED**

GSD

**SEX**

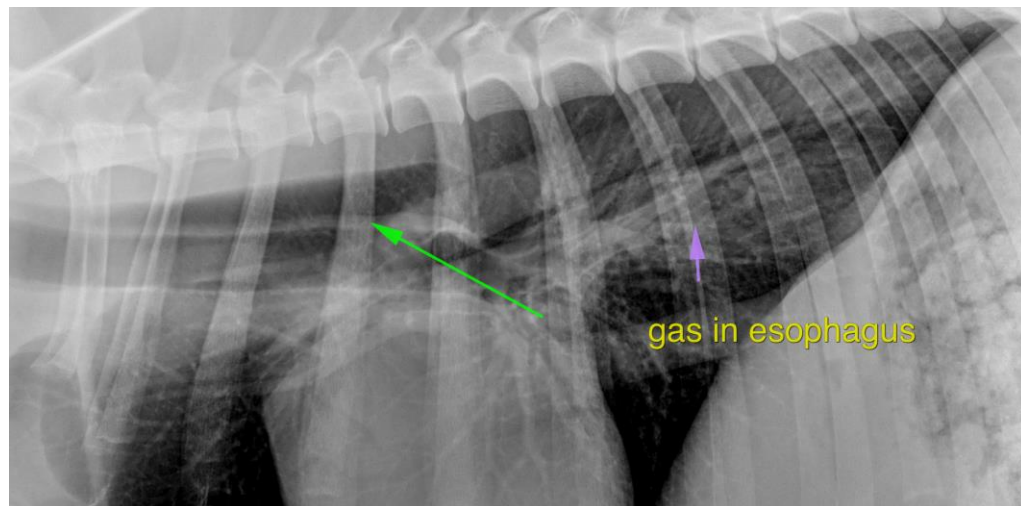
Female

**AGE**

1.5 Years

**INTERPRETED BY**

Nele Eley, DVM  
Dr. med. Vet. DipECVDI



**HOSPITAL NAME**

The Pet Hospital of  
Stratford

The information and recommendations provided are based on the images presented by the referring veterinarian/sonographer. No evaluation can be communicated regarding pathology that was not visible in the image/video clips provided.

**REFERRING VET**

Dr Giuliani

Thank you for this referral. If the clinical or image interpretation does not parallel your findings or if I can be of any further assistance please contact me.

**Nele Eley**, DVM, Dr. med. vet., DipECVDI  
European Specialist in Veterinary Diagnostic Imaging, Cert. Radiology,  
Senior lecturer University of Giessen, Germany, Veterinary Faculty, Department of Radiology  
Nele.Eley@sonopath.com

**INVOICE**

56740

**DATE**

2-14-23