



PATIENT

Piper Ildiz

PRESENTING CLINICAL SIGNS

Owner is fostering a dog with kennel cough, Piper has been coughing, and not eating since Friday
Abnormal PE/Chem/CBC/UA Results: Pending

SPECIES

Canine

RADIOGRAPHIC STUDY OF THE THORAX

Single right lateral view available for review.

BREED

Mixed

RADIOGRAPHIC FINDINGS

The degree of pulmonary inflation is moderate. A moderate generalized bronchointerstitial lung pattern with mild caudodorsal accentuation is noted.

SEX

Female Spayed

A redundant dorsal tracheal ligament of the cervical and cranial thoracic trachea is present.

The vertebral heart score is 10.5.

There is no evidence of mediastinal lymphadenomegaly or other pathologic mediastinal widening.

AGE

4 Years

No signs of pleural effusion are noted.

The thoracic boundaries present within normal limits.

INTERPRETED BY

Nele Eley, DVM
Dr. med. Vet. DipECVDI

RADIOGRAPHIC DIAGNOSIS

- Moderate bronchointerstitial lung pattern.
- Redundant dorsal tracheal ligament
- Minimal generalized cardiomegaly

HOSPITAL NAME

New Bridge
Veterinary Practice

INTERPRETATION OF THE FINDINGS & FURTHER RECOMMENDATIONS

The radiographic findings do suggest potential for lower airway disease including canine infectious respiratory disease complex and “infectious” tracheobronchitis. Allergic lower airway disease and other infectious bronchitis is a potential too. However, due to the occurrence of kennel cough in the household, this appears to be the most prudent tentative diagnosis.

REFERRING VET

Dr. Abina Glennon

The minimal cardiac enlargement does not necessarily imply presence of cardiac pathology. Anemia, bradycardia, or fever in conjunction with the presumed respiratory disease as well as diastolic exposure can cause borderline enlargement of the cardiac silhouette.

INVOICE

56710

Redundancy of the dorsal tracheal ligament can be an incidental finding. It can be associated with dynamic tracheal disease especially in predisposed breeds.

DATE

2-13-23



PATIENT

Piper Ildiz

SPECIES

Canine

BREED

Mixed

SEX

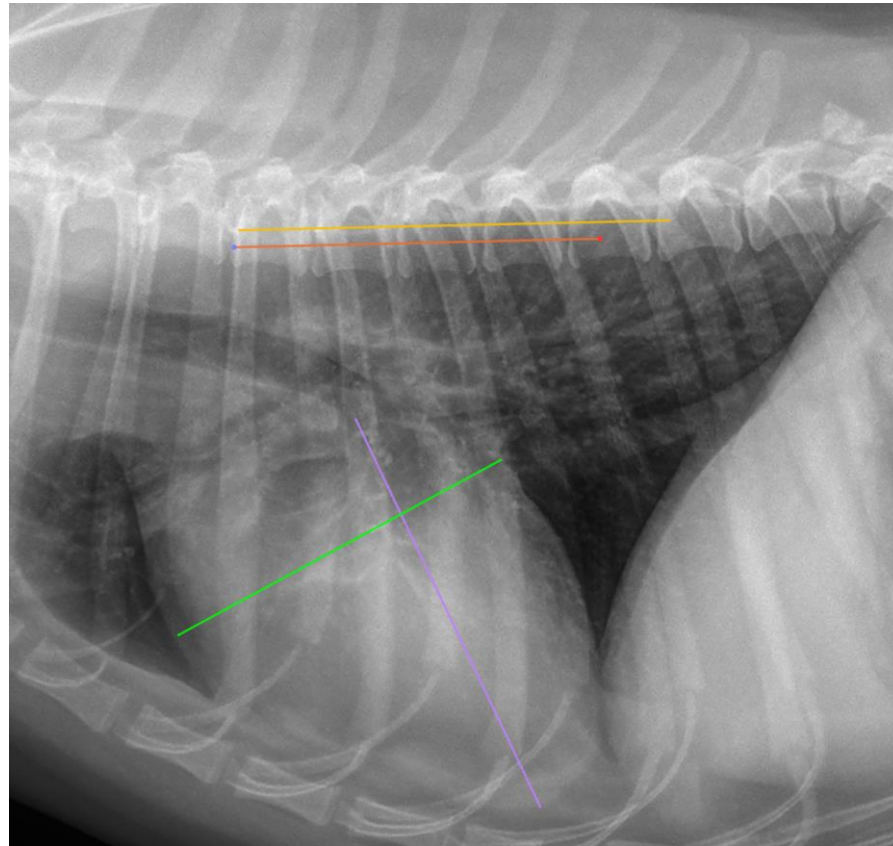
Female Spayed

AGE

4 Years

INTERPRETED BY

Nele Eley, DVM
Dr. med. Vet. DipECVDI



HOSPITAL NAME

New Bridge
Veterinary Practice

REFERRING VET

Dr. Abina Glennon

INVOICE

56710

DATE

2-13-23

The information and recommendations provided are based on the images presented by the referring veterinarian/sonographer. No evaluation can be communicated regarding pathology that was not visible in the image/video clips provided.

Thank you for this referral. If the clinical or image interpretation does not parallel your findings or if I can be of any further assistance please contact me.

Nele Eley, DVM, Dr. med. vet., DipECVDI
European Specialist in Veterinary Diagnostic Imaging, Cert. Radiology,
Senior lecturer University of Giessen, Germany, Veterinary Faculty, Department of Radiology
Nele.Eley@sonopath.com