

**PATIENT PRESENTING CLINICAL SIGNS**

Mossimo Cutter Nasal discharge

COMPUTED TOMOGRAPHIC STUDY OF THE HEAD**SPECIES**

Plain and post contrast studies available for review.

Feline

COMPUTED TOMOGRAPHIC FINDINGS**BREED**

DSH

Severe turbinate destruction is noted within both nasal cavities. There is deformity and asymmetry of the nasal bones as well as leftward deviation of the bony nasal septum. Moderate irregular swelling of the mucosal lining of the nasal cavities is seen. There is mild bilateral frontal sinus hyperostosis, deformity of the cribriform plate, and mild bilateral frontal sinus fluid accumulation.

SEX

Neutered Male

The bilateral retropharyngeal and submandibular lymph nodes present mild symmetric enlargement.

The dentition is incomplete. Multiple absent tooth elements, root remnants, and resorptive changes of the remaining tooth roots are seen. There is no evidence of a dental-nasal fistula.

AGE

11 Years

COMPUTED TOMOGRAPHIC DIAGNOSIS

- Severe bilateral chronic destructive rhinosinusitis with nasal deformity.
- Mild bilateral medial retropharyngeal and submandibular lymphadenomegaly.

INTERPRETED BYNele Eley (Ondreka),
DVM Dr. med. vet.,
DipECVDI**INTERPRETATION OF FINDINGS & FURTHER RECOMMENDATIONS**

The CT study reveals severe bilateral destructive rhinosinusitis. Fungal rhinitis is considered the primary differential diagnosis, especially infection with aspergillus or cryptococcus species should be considered. Other chronic infectious rhinitis such as bacterial and viral cannot be ruled out entirely but is thought by far less likely.

The lymph node changes are compatible with reactive lymphadenitis.

HOSPITAL NAME

Mobile Pet Imaging

REFERRING VET

Meaux

INVOICE

56510

DATE

2-1-23



PATIENT

Mossimo Cutter

SPECIES

Feline

BREED

DSH

SEX

Neutered Male

AGE

11 Years

INTERPRETED BY

Nele Eley (Ondreka),
DVM Dr. med. vet.,
DipECVDI

HOSPITAL NAME

Mobile Pet Imaging

REFERRING VET

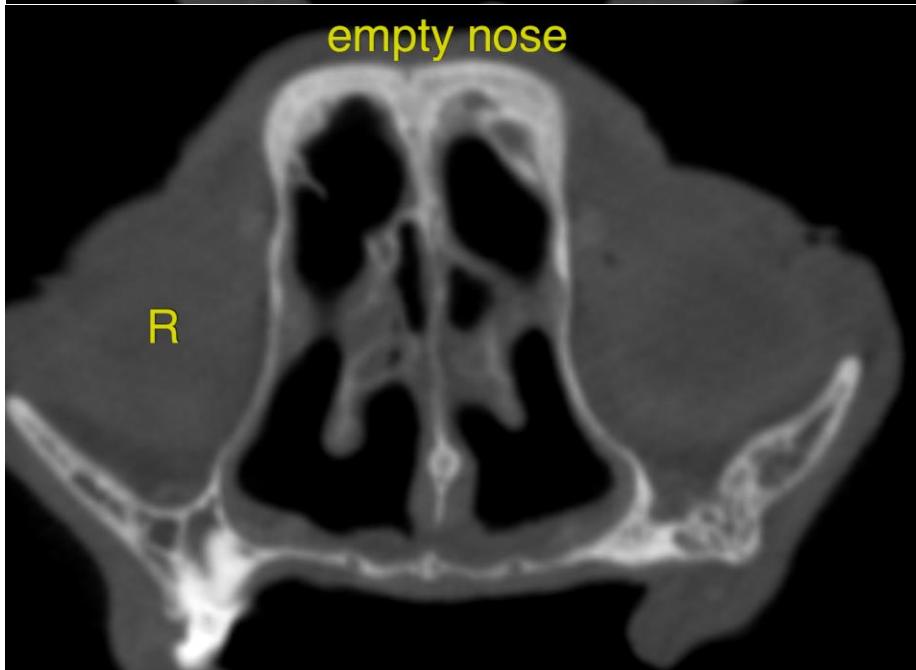
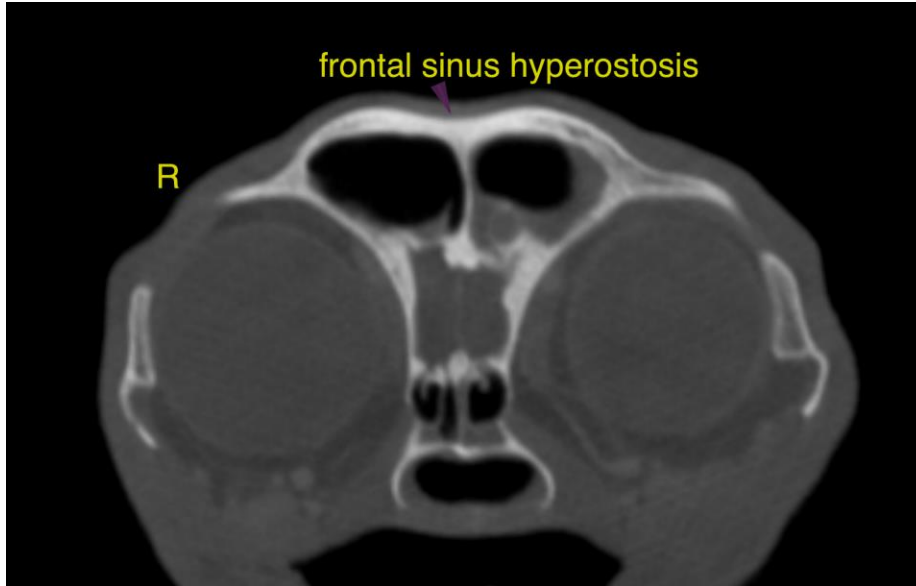
Meaux

INVOICE

56510

DATE

2-1-23



**PATIENT**

Mossimo Cutter

The information and recommendations provided are based on the images presented by the referring veterinarian. No evaluation can be communicated regarding pathology that was not visible in the image/video clips provided.

SPECIES

Feline

Thank you for this referral. If the clinical or image interpretation does not parallel your findings or if I can be of any further assistance please contact me.

BREED

DSH

Nele Eley (Ondreka), DVM, Dr. med. vet., DipECVDI
European Specialist in Veterinary Diagnostic Imaging, Cert. Radiology,
Senior lecturer University of Giessen/Germany, Veterinary Faculty, Department of Radiology.
Nele.Eley@sonopath.com

SEX

Neutered Male

AGE

11 Years

INTERPRETED BY

Nele Eley (Ondreka),
DVM Dr. med. vet.,
DipECVDI

HOSPITAL NAME

Mobile Pet Imaging

REFERRING VET

Meaux

INVOICE

56510

DATE

2-1-23