

**PATIENT**

Vannie Glover

PRESENTING CLINICAL SIGNS

vomiting bile hasn't been eating today yowled start vomiting early morning every day . Needs to check any possible GI foreign body

SPECIES

Feline

RADIOGRAPHIC STUDY OF THE THORAX

Right lateral and ventrodorsal whole body views totaling 2 images available for review in jpeg format.

BREED

Domestic Shorthair

Thoracic read requested.

SEX

Neutered Male

RADIOGRAPHIC FINDINGS

An ovoid soft tissue opacity is seen in the caudodorsal thorax which appears to have a broad base to the diaphragmatic crura and appears to correspond to a soft tissue opacity superimposed onto the 13th thoracic vertebra in the midline on the orthogonal view.

AGE

10 Years

The lung presents a mild generalized bronchial pattern.

No radiographic evidence of cardiovascular pathology is seen.

The course and width of the trachea are considered within normal limits.

Mild cervical and thoracic esophageal aerophagia are seen.

INTERPRETED BY

Nele Eley, DVM
Dr. med. Vet. DipECVDI

There is no evidence of aspiration pneumonia.

RADIOGRAPHIC DIAGNOSIS

- Caudodorsal mediastinal soft tissue opacity.

HOSPITAL NAME

Wilson Road Vet
Clinic

INTERPRETATION OF THE FINDINGS & FURTHER RECOMMENDATIONS

The radiographic findings are suggestive for hiatal hernia with intermittent or permanent malpositioning of the lower esophageal sphincter cranial of the diaphragmatic crura. Esophageal foreign material or mediastinal mass are possible but less likely differential diagnoses.

REFERRING VET

Dr. Ehab Yessa

Presence of abdominal pathology should be ruled out by means of abdominal ultrasound if not performed already.

INVOICE

50015

DATE

2-1-22



PATIENT

Vannie Glover

SPECIES

Feline

BREED

Domestic Shorthair

SEX

Neutered Male

AGE

10 Years

INTERPRETED BY

Nele Eley, DVM
Dr. med. Vet. DipECVDI

HOSPITAL NAME

Wilson Road Vet
Clinic

REFERRING VET

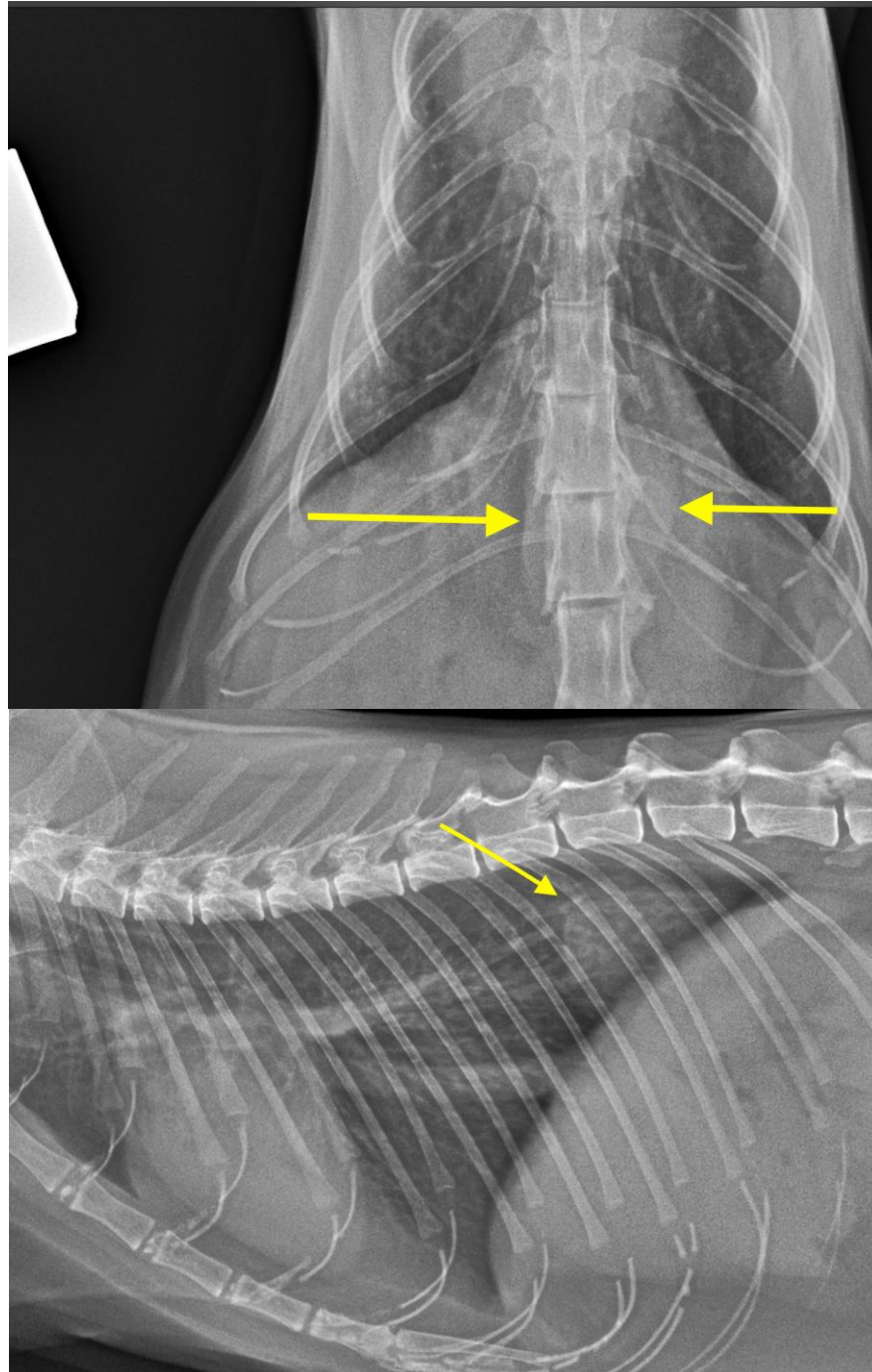
Dr. Ehab Yessa

INVOICE

50015

DATE

2-1-22





PATIENT

Vannie Glover

The information and recommendations provided are based on the images presented by the referring veterinarian/sonographer. No evaluation can be communicated regarding pathology that was not visible in the image/video clips provided.

Thank you for this referral. If the clinical or image interpretation does not parallel your findings or if I can be of any further assistance please contact me.

SPECIES

Feline

Nele Eley, DVM, Dr. med. vet., DipECVDI
European Specialist in Veterinary Diagnostic Imaging, Cert. Radiology,
Senior lecturer University of Giessen, Germany, Veterinary Faculty, Department of Radiology
Nele.Eley@sonopath.com

BREED

Domestic Shorthair

SEX

Neutered Male

AGE

10 Years

INTERPRETED BY

Nele Eley, DVM
Dr. med. Vet. DipECVDI

HOSPITAL NAME

Wilson Road Vet
Clinic

REFERRING VET

Dr. Ehab Yessa

INVOICE

50015

DATE

2-1-22