



PATIENT

Brantley Fedak

SPECIES

Canine

BREED

Staffordshire Terrier

SEX

Neutered Male

AGE

9Y

WEIGHT

78lbs

INTERPRETED BY

Nele Eley (Ondreka),
DVM Dr. med. vet.,
DipECVDI

IMAGING PERFORMED BY

Mallory Frois

HOSPITAL NAME

The Pet Hospital of
Stratford

REFERRING VET

Dr. Robert Bashkin

INVOICE

72934

DATE

12-9-25

PRESENTING CLINICAL SIGNS

P came in limping on right hind from outside on Sunday. O unsure what happened. Toe became swollen the next day.

Abnormal PE/Chem/CBC/UA Results: D5 on right hind swollen, non-painful on palpation. No wounds or obvious fb noted. P toe-touching

RADIOGRAPHIC STUDY OF THE RIGHT HIND PAW

Mediolateral and craniocaudal views of the right hind paw totaling 2 images available for review.

RADIOGRAPHIC FINDINGS

A complete sagittal fracture of the middle phalanx is present in the 5th digit of the right hind paw extending from the proximal articular surface to the distal articular surface. Moderate fracture displacement with cortical step formation and malalignment is seen. There is moderate peripheral soft tissue swelling of the 5th digit. No radiopaque foreign material is identified. There is no evidence of regional emphysema, and no areas of aggressive bone lysis are detectable.

RADIOGRAPHIC DIAGNOSIS

- Complete sagittal fracture of P2 right hind digit 5 with moderate displacement and moderate regional soft tissue swelling.

INTERPRETATION OF FINDINGS & FURTHER RECOMMENDATIONS

The findings are consistent with a traumatic fracture of the middle phalanx of the 5th digit in the right hind paw. Evidence of aggressive bone lysis is not seen. The soft tissue swelling is likely secondary to the trauma and may represent hematoma as well as reactive inflammation. Orthopedic consultation for fracture management such as splinting vs open reduction and internal fixation can be considered if not performed already.



PATIENT

Brantley Fedak

SPECIES

Canine

BREED

Staffordshire Terrier

SEX

Neutered Male

AGE

9Y

WEIGHT

78lbs

INTERPRETED BY

Nele Eley (Ondreka),
DVM Dr. med. vet.,
DipECVDI

IMAGING PERFORMED BY

Mallory Frois

HOSPITAL NAME

The Pet Hospital of
Stratford

REFERRING VET

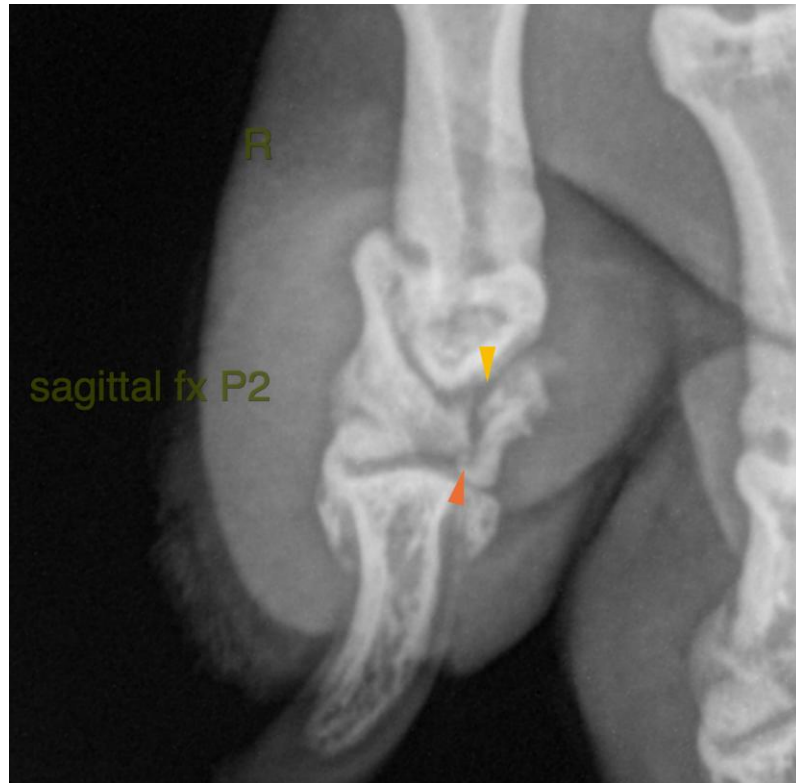
Dr. Robert Bashkin

INVOICE

72934

DATE

12-9-25



The information and recommendations provided are based on the images presented by the referring veterinarian. No evaluation can be communicated regarding pathology that was not visible in the image/video clips provided.

Thank you for this referral. If the clinical or image interpretation does not parallel your findings or if I can be of any further assistance please contact me.

Nele Eley (Ondreka), DVM, Dr. med. vet., DipECVDI
European Specialist in Veterinary Diagnostic Imaging, Cert. Radiology,
Senior lecturer University of Giessen/Germany, Veterinary Faculty, Department of Radiology.
info@sonopath.com