



PATIENT

Annabelle Pozuello

SPECIES

Feline

BREED

Domestic Longhair

SEX

Female Spayed

AGE

14Y, 3M, 29D

WEIGHT

10.8lbs

INTERPRETED BY

Nele Eley (Ondreka),
DVM Dr. med. vet.,
DipECVDI

IMAGING PERFORMED BY

Joseph D'Abbraccio, DVM

HOSPITAL NAME

Catskill Veterinary
Services, PLLC

REFERRING VET

Joseph D'Abbraccio, DVM

INVOICE

72933

DATE

12-9-25

PRESENTING CLINICAL SIGNS

10/24/2025: Reason for Visit: Evaluation of mass and heart murmur in feline. History: Owner presented Annabelle due to a mass. Owner reported a history of two litters and that Annabelle was spayed at approximately four years of age. Owner mentioned a previously noted heart murmur and requested confirmation and recommendations for workup prior to anesthesia. Owner observed spots of blood in the area of the mass and noted the mass has grown since first discovered. No weight was obtained at the time of visit. Owner expressed concern regarding pain and postoperative care, including keeping Annabelle separate from other cats in the household. 12/9/2025: Annabelle presents today for CT. Any Concerns: Yes: Mass bleeds and scabs at times Any medications and/or supplements: Gabapentin What time were medications given?: 8 AM Last Meal?: 10pm last night Abnormal PE/Chem/CBC/UA Results: PE: Cardiovascular: Grade II/VI heart murmur.; Integument: Mass on cranial right mammary chain, increased in size since initial discovery.; Urinary/Urogenital: Mass present on the cranial right mammary gland. Evidence of blood present in the mammary tissue. Mass described as having increased in size since first discovered.; CBC: Monocytes 0.676; Basophils 0.132; Chem: K 3.4; TCO2 23;

COMPUTED TOMOGRAPHIC STUDY OF THE THORAX & ABDOMEN

Plain and post contrast studies of the thorax and abdomen are available for review.

COMPUTED TOMOGRAPHIC FINDINGS

Thorax

Multiple thoracolumbar spondyloses are seen.

Mammary mass: the right cranial mammary mass is ill-defined with finger like tendrils in the periphery. Mass and tendrils altogether measure approximately 40 x 30 x 20mm. The mass presents strong heterogeneous contrast enhancement.

The right axillary lymph node is moderately enlarged measuring 10mm in diameter with heterogeneous enhancement and ill-defined margins.

The sternal, cranial mediastinal and tracheobronchial lymph nodes are small elongated with a normal short-to-long-axis-ratio is < 0.5, the attenuation and contrast enhancement pattern are uniform and considered within normal limits. No mediastinal masses are noted.

The cardiovascular structures including the pulmonary vasculature are within normal limits.

There is no evidence of pulmonary nodules or masses.

A mild generalized bronchial pattern is noted throughout the lung with lobar atelectasis of the right middle lung lobe.

Small incidental gas pockets are seen within the esophageal lumen; there is no evidence of abnormal dilation.

Abdomen

The serosal fat presents normal attenuation behavior. There is no evidence of peritoneal effusion or peritonitis.



PATIENT

Annabelle Pozuello

SPECIES

Feline

BREED

Domestic Longhair

SEX

Female Spayed

AGE

14Y, 3M, 29D

WEIGHT

10.8lbs

INTERPRETED BY

Nele Eley (Ondreka),
DVM Dr. med. vet.,
DipECVDI

IMAGING PERFORMED BY

Joseph D'Abbraccio, DVM

HOSPITAL NAME

Catskill Veterinary
Services, PLLC

REFERRING VET

Joseph D'Abbraccio, DVM

INVOICE

72933

DATE

12-9-25

Both kidneys present within normal limits for size, shape and organ architecture. After contrast administration, a bilaterally symmetric and uniform nephro- and pyelogram is noted.

The adrenal glands are within normal limits for size, shape and organ architecture.

Both liver and spleen present with normal shape, even surface, uniformly attenuating parenchyma and homogeneous contrast enhancement, unremarkable.

The pancreas is evenly contoured; the pancreatic parenchyma is homogeneous and presents uniform contrast enhancement.

The small intestine shows generalized mild increase in muscularis/mucosa ratio.

No evidence of lymphadenopathy is seen.

COMPUTED TOMOGRAPHIC DIAGNOSIS

- Right cranial mammary mass meeting neoplastic criteria with presumed aggressive biological behavior.
- Right axillary lymphadenomegaly compatible with metastatic disease.
- No evidence of pulmonary or abdominal metastasis.
- Mild generalized bronchial lung pattern with focal right middle lobe atelectasis – may indicate feline asthma.
- Nonspecific small intestinal increase in muscularis/mucosa ratio.

INTERPRETATION OF FINDINGS & FURTHER RECOMMENDATIONS

The right cranial mammary mass demonstrates infiltrative margins with tendrils suggesting locally aggressive behavior. The findings are compatible with mammary carcinoma.

The right axillary lymph node enlargement is likely to represent regional metastasis. Correlation with FNA or biopsy is recommended.

Evidence of pulmonary metastasis is not seen.

The pulmonary changes may reflect chronic lower airway disease such as allergic with mucous plugging and irreversible atelectasis of the right middle lobe.

The mild increase small intestinal muscularis/mucosa ratio is subtle and nonspecific.

The findings of the lung and GI tract may be incidental. Clinical correlation is advised.



PATIENT

Annabelle Pozuello

SPECIES

Feline

BREED

Domestic Longhair

SEX

Female Spayed

AGE

14Y, 3M, 29D

WEIGHT

10.8lbs

INTERPRETED BY

Nele Eley (Ondreka),
DVM Dr. med. vet.,
DipECVDI

IMAGING PERFORMED BY

Joseph D'Abbraccio, DVM

HOSPITAL NAME

Catskill Veterinary
Services, PLLC

REFERRING VET

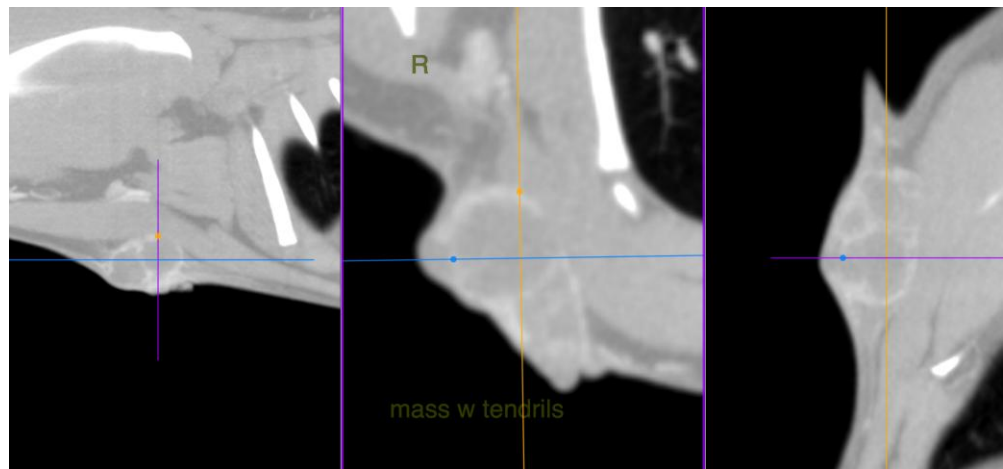
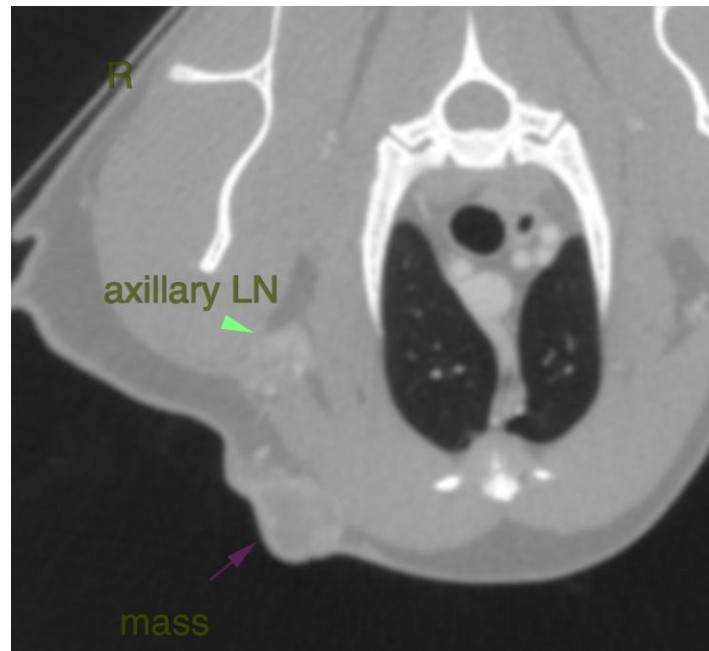
Joseph D'Abbraccio, DVM

INVOICE

72933

DATE

12-9-25



The information and recommendations provided are based on the images presented by the referring veterinarian. No evaluation can be communicated regarding pathology that was not visible in the image/video clips provided.

Thank you for this referral. If the clinical or image interpretation does not parallel your findings or if I can be of any further assistance please contact me.

Nele Eley (Ondreka), DVM, Dr. med. vet., DipECVDI
European Specialist in Veterinary Diagnostic Imaging, Cert. Radiology,
Senior lecturer University of Giessen/Germany, Veterinary Faculty, Department of Radiology.
info@sonopath.com