


PATIENT PRESENTING CLINICAL SIGNS

Zippy Ruben Head tilt to left. Recent onset blindness and no obvious ocular lesions.

COMPUTED TOMOGRAPHIC STUDY OF THE HEAD
SPECIES

Plain and post-contrast studies available for review.

Canine

COMPUTED TOMOGRAPHIC FINDINGS
BREED

Two ovoid, approximately 5.0 mm sized, enhancing lesions with mass effect are seen to the right of the midline, level with the thalamus and hypothalamus. Mild bilaterally symmetrical lateral ventriculomegaly is seen. The pituitary gland presents within normal limits.

Papillon

Thin and smoothly folded conchae and turbinates with even smooth mucosal lining.

SEX

Both temporomandibular joints present congruent joint spaces with even subchondral bone surfaces and are considered within normal limits.

Female

AGE

Minimal focal mucosal swelling is seen within the left tympanic bulla. The right tympanic bulla presents within normal limits. The external auditory meatuses present within normal limits.

10 Years

The submandibular and medial retropharyngeal lymph nodes are small and elongated with a normal short-to-long-axis-ratio is < 0.5, the attenuation and contrast enhancement pattern is uniform.

The salivary glands present within normal limits.

INTERPRETED BY

Nele Eley (Ondreka),
 DVM Dr. med. vet.,
 DipECVDI

The dentition is incomplete. Multifocal severe periodontal disease accentuating the triadans #107, 108, 207, 208, 307, 308, 309, 310, 404, 407, 408, 409, 410 is seen.

COMPUTED TOMOGRAPHIC DIAGNOSIS

- Two intraaxial enhancing lesions with mass effect level with the right hypothalamus and thalamus
- Multifocal severe periodontal disease

HOSPITAL NAME

Blairstown AH

INTERPRETATION OF FINDINGS & FURTHER RECOMMENDATIONS
REFERRING VET

Dr. Summers

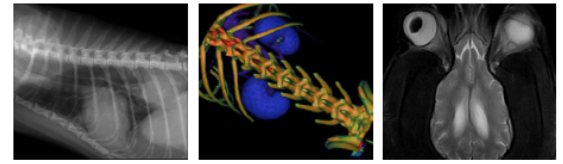
The CT study reveals two intraaxial lesions with contrast enhancement and mild mass effect level with the right thalamus and hypothalamus. Differential diagnosis include secondary neoplasia such as metastatic disease of another primary tumor and round cell neoplasia as well as less likely inflammatory/infectious encephalopathy and acute hemorrhagic cerebral vascular events.

INVOICE

33381

DATE

12/9/21



PATIENT

Zippy Ruben

SPECIES

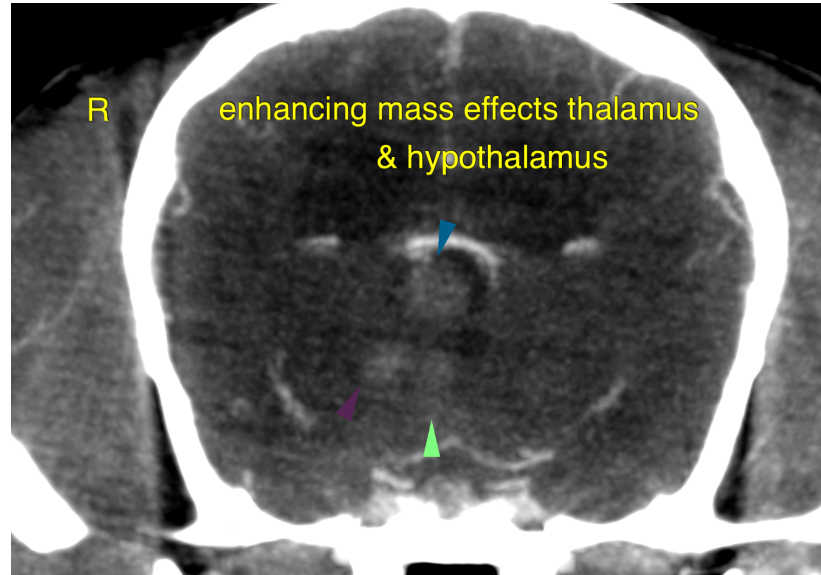
Canine

BREED

Papillon

SEX

Female



AGE

10 Years

The information and recommendations provided are based on the images presented by the referring veterinarian. No evaluation can be communicated regarding pathology that was not visible in the image/video clips provided.

Thank you for this referral. If the clinical or image interpretation does not parallel your findings or if I can be of any further assistance please contact me.

INTERPRETED BY

Nele Eley (Ondreka),
DVM Dr. med. vet.,
DipECVDI

Nele Eley (Ondreka), DVM, Dr. med. vet., DipECVDI
European Specialist in Veterinary Diagnostic Imaging, Cert. Radiology,
Senior lecturer University of Giessen/Germany, Veterinary Faculty, Department of Radiology.
Nele.Eley@sonopath.com

HOSPITAL NAME

Blairstown AH

REFERRING VET

Dr. Summers

INVOICE

33381

DATE

12/9/21