


**PATIENT PRESENTING CLINICAL SIGNS**

Josie Mitchell Been consistently throwing up for a couple of days, but she has been throwing up off and on for the course of a month. There has been no change in food or treats. They are eating Whole Earth Farms and she has been eating this ever since she was a puppy. Josie is the only dog at home throwing up. Starting this morning she has been whining before throwing up like she is in pain. She throws up food and bile.

**SPECIES**

Canine Abnormal PE/Chem/CBC/UA Results: SLIGHT DEHYDRATED MALOCCUTION, OVERBITE

**RADIOGRAPHIC STUDY OF THE ABDOMEN**
**BREED**

Right/left lateral and ventrodorsal views provided for review, totaling 4 images.

Pit Bull

**RADIOGRAPHIC FINDINGS**
**SEX**

The surrounding bony structures are within normal limits.

Female

No abnormalities of the extra-abdominal soft tissues are noted. The abdominal wall is smooth and thin.

The serosal detail is maintained throughout the peritoneal and retroperitoneal space.

**AGE**

The liver is appropriate in position and size and presents uniform opacity.

56.4 Pounds

The splenic head is in the anticipated position and within normal limits for size and opacity. The splenic body and tail are considered normal for position, size, shape, and opacity.

**INTERPRETED BY**

Nele Eley (Ondreka),  
 DVM Dr. med. vet.,  
 DipECVDI

Both kidneys are seen and present with normal size, shape, delineation, and opacity. The urinary bladder is in its anticipated position. No radiopaque calculi are noted throughout the upper and lower urinary tract.

The stomach is filled with a mild amount of gas. No abnormal dilation. There is no evidence of radiopaque foreign material. The small intestinal loops are of even diameter and evenly distributed throughout the mid abdomen. A mild amount of fecal material is seen in the ascending and descending colon respectively. I cannot delineate radiopaque foreign material, and there is no abnormal small intestinal dilation or plication.

**HOSPITAL NAME**

Elizabeth AH

**RADIOGRAPHIC DIAGNOSIS**
**REFERRING VET**

Dr. Kim Allyn

- Gastrointestinal maldigestion pattern
- No radiographic evidence of mechanical ileus

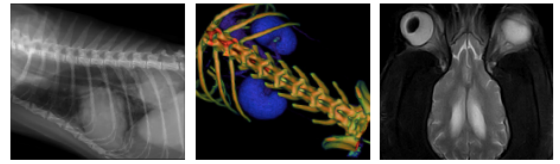
**INTERPRETATION OF FINDINGS & FURTHER RECOMMENDATIONS**
**INVOICE**

33400

The radiographic study reveals no signs of mechanical ileus. Subileus and paralytic/functional ileus are potential considerations. Further definition by means of ultrasound should be considered should the patient's clinical signs persist despite the initiated management. Narrow clinical monitoring is advised.

**DATE**

12/9/21



**PATIENT**

Josie Mitchell

**SPECIES**

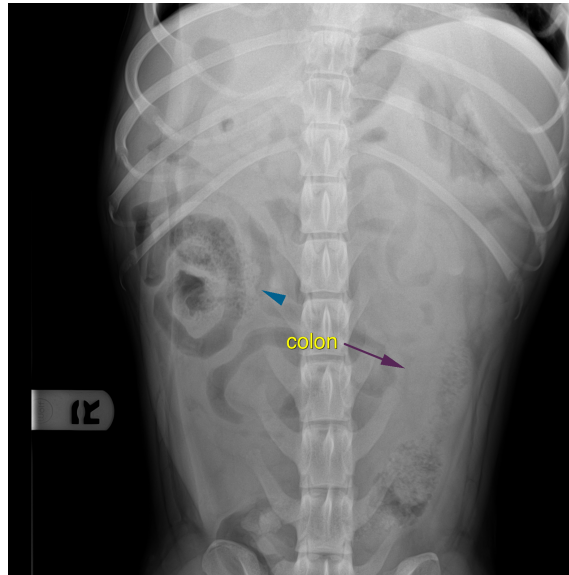
Canine

**BREED**

Pit Bull

**SEX**

Female



**AGE**

56.4 Pounds

The information and recommendations provided are based on the images presented by the referring veterinarian. No evaluation can be communicated regarding pathology that was not visible in the image/video clips provided.

Thank you for this referral. If the clinical or image interpretation does not parallel your findings or if I can be of any further assistance please contact me.

**INTERPRETED BY**

Nele Eley (Ondreka),  
DVM Dr. med. vet.,  
DipECVDI

**Nele Eley (Ondreka)**, DVM, Dr. med. vet., DipECVDI  
European Specialist in Veterinary Diagnostic Imaging, Cert. Radiology,  
Senior lecturer University of Giessen/Germany, Veterinary Faculty, Department of Radiology.  
Nele.Eley@sonopath.com

**HOSPITAL NAME**

Elizabeth AH

**REFERRING VET**

Dr. Kim Allyn

**INVOICE**

33400

**DATE**

12/9/21