
**PATIENT PRESENTING CLINICAL SIGNS**

Ellie Brown Patient seen originally for RPL lameness, but at the same time noticed palpably large swelling of medial thigh. Isolated to muscle group; semi-tendinosus area. Painful when palpate. Lesion not present on right side.

**SPECIES COMPUTED TOMOGRAPHIC STUDY OF THE PELVIS & LEFT HINDLIMB (PELVIS TO STIFLE)**

Canine Plain and post-contrast studies available for review.

**BREED COMPUTED TOMOGRAPHIC FINDINGS**

German Shepherd Both coxofemoral joints present within normal limits. The pelvic bones present within normal limits. There is no abnormality of the lumbosacral joint seen. The left stifle joint present within normal limits.

**SEX** The medial thigh muscles of the left hindlimb including the gracilis, semitendinosus, semimembranosus and femoral biceps all present within normal limits in terms of their shape, delineation, attenuation and enhancement.

Spayed Female The popliteal lymph node presents within normal limits as well.

**AGE COMPUTED TOMOGRAPHIC DIAGNOSIS**

6 Years
 

- Normal CT findings of the pelvis and left hindlimb

**INTERPRETED BY INTERPRETATION OF FINDINGS & FURTHER RECOMMENDATIONS**

Nele Eley (Ondreka),  
 DVM Dr. med. vet.,  
 DipECVDI

The CT study of the pelvis and left hindlimb reveals no evidence of structural pathology. I cannot delineate a mass or discreet swelling in the left medial thigh. However, volume changes of the gracilis or semitendinosus cannot be ruled out entirely, even though their structure appearance within normal limits. Moreover, stage 1 structural muscle fiber damage can be occult on imaging. Hence, gracilis or semitendinosus myopathy cannot be ruled out entirely, especially in light of the patient demographics. These should be general considerations.

**HOSPITAL NAME**

Southern Oregon Vet  
 Specialty Center

If possible, a side by side comparison of both limbs with symmetric positioning of the patient can help in such cases.

**REFERRING VET**

Dr. Fugazzi

**INVOICE**

33377

**DATE**

12/9/21



**PATIENT**

Ellie Brown

**SPECIES**

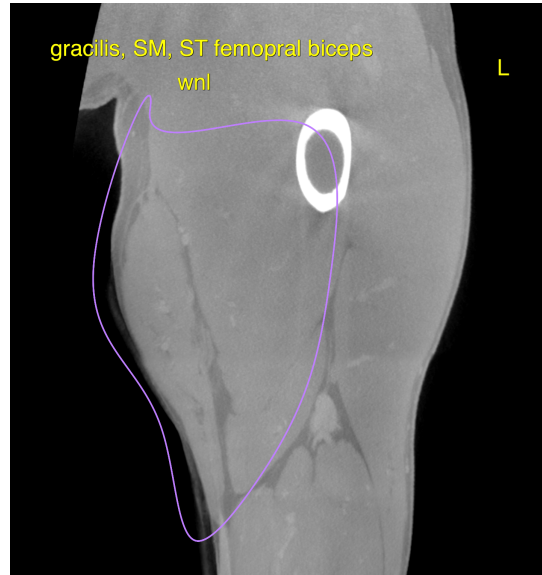
Canine

**BREED**

German Shepherd

**SEX**

Spayed Female



**AGE**

6 Years

The information and recommendations provided are based on the images presented by the referring veterinarian. No evaluation can be communicated regarding pathology that was not visible in the image/video clips provided.

Thank you for this referral. If the clinical or image interpretation does not parallel your findings or if I can be of any further assistance please contact me.

**INTERPRETED BY**

Nele Eley (Ondreka),  
DVM Dr. med. vet.,  
DipECVDI

**Nele Eley (Ondreka)**, DVM, Dr. med. vet., DipECVDI  
European Specialist in Veterinary Diagnostic Imaging, Cert. Radiology,  
Senior lecturer University of Giessen/Germany, Veterinary Faculty, Department of Radiology.  
Nele.Eley@sonopath.com

**HOSPITAL NAME**

Southern Oregon Vet  
Specialty Center

**REFERRING VET**

Dr. Fugazzi

**INVOICE**

33377

**DATE**

12/9/21