



## PATIENT

Nugget Su

## SPECIES

Canine

## BREED

Pembroke Welsh Corgi

## SEX

FS

## AGE

3Y

## WEIGHT

24lbs

## INTERPRETED BY

Nele Eley (Ondreka),  
DVM Dr. med. vet.,  
DipECVDI

## IMAGING PERFORMED BY

Dr. Barnea

## HOSPITAL NAME

Tenafly Vet Center

## REFERRING VET

Dr. Barnea

## INVOICE

72893

## DATE

12-8-25

## PRESENTING CLINICAL SIGNS

chest chronic cough after boarding not responding to clavamox

## RADIOGRAPHIC STUDY OF THE THORAX

Right/left lateral and ventrodorsal views of the thorax totaling 3 images available for review.

## RADIOGRAPHIC FINDINGS

The cardiac silhouette is normal in size and morphology without evidence of chamber enlargement. The VHS is 10.3.

The trachea is normal in caliber and course with no evidence of collapse or deviation.

A moderate generalized bronchial lung pattern is noted with mild peribronchial cuffing. The bronchial wall enhancement is most pronounced in the caudodorsal lung fields. No evidence of pulmonary nodules, masses, or alveolar consolidation is seen.

The pleural space and mediastinum are clear.

## RADIOGRAPHIC DIAGNOSIS

- Moderate bronchial lung pattern consistent with bronchitis or allergic airway disease.
- Mild peribronchial cuffing reflecting airway inflammation.
- Normal radiographic presentation of cardiovascular structures and trachea.

## INTERPRETATION OF FINDINGS & FURTHER RECOMMENDATIONS

The imaging findings are consistent with chronic primarily bronchial airway disease. Differential diagnosis includes inflammatory/allergic airway inflammation vs infectious bronchitis. The lack of response to antibiotics supports a nonbacterial cause such as inflammatory/allergic or viral/parasitic. Consider a clinical trial of anti-inflammatory therapy, environmental management to reduce airway irritants, and airway endoscopy with airway sampling in case of lacking response to medical management.



## PATIENT

Nugget Su

## SPECIES

Canine

## BREED

Pembroke Welsh Corgi

## SEX

FS

## AGE

3Y

## WEIGHT

24lbs

## INTERPRETED BY

Nele Eley (Ondreka),  
DVM Dr. med. vet.,  
DipECVDI

## IMAGING PERFORMED BY

Dr. Barnea

## HOSPITAL NAME

Tenafly Vet Center

## REFERRING VET

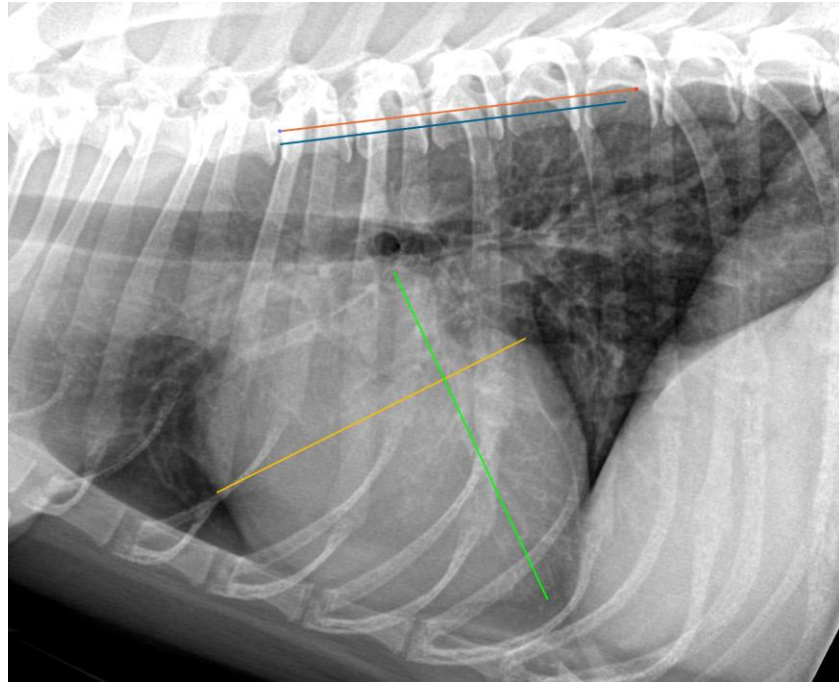
Dr. Barnea

## INVOICE

72893

## DATE

12-8-25



The information and recommendations provided are based on the images presented by the referring veterinarian. No evaluation can be communicated regarding pathology that was not visible in the image/video clips provided.

Thank you for this referral. If the clinical or image interpretation does not parallel your findings or if I can be of any further assistance please contact me.

**Nele Eley (Ondreka)**, DVM, Dr. med. vet., DipECVDI  
European Specialist in Veterinary Diagnostic Imaging, Cert. Radiology,  
Senior lecturer University of Giessen/Germany, Veterinary Faculty, Department of Radiology.  
[info@sonopath.com](mailto:info@sonopath.com)