



PATIENT

Archie Wilson

SPECIES

Canine

BREED

Cocker Spaniel

SEX

M

AGE

1Y, 2M

WEIGHT

15.4

INTERPRETED BY

Nele Eley (Ondreka),
DVM Dr. med. vet.,
DipECVDI

IMAGING PERFORMED BY

Patricia Sanchez
Sanchez

HOSPITAL NAME

Animal Trust - Bolton

REFERRING VET

Patricia Sanchez Sanchez

INVOICE

72884

DATE

12-8-25

PRESENTING CLINICAL SIGNS

Swelling on frontal bone of skull got better after metacam but then swelled up again. Large firm swelling over R frontal bone of cranium, discomfort on palpation
Abnormal PE/Chem/CBC/UA Results: NAD

COMPUTED TOMOGRAPHIC STUDY OF THE HEAD

Plain and post contrast studies are available for review.

COMPUTED TOMOGRAPHIC FINDINGS

The CT study reveals an ill-defined cavitory lesion measuring approximately 5 x 4 x 3 cm in the right frontal region with thick enhancing rim enhancement and fluid attenuating center. The lesion demonstrates extension into the temporal region. Surrounding soft tissue swelling is evident. Evidence of foreign material is not seen. There is no evidence of osseous involvement.

The right retropharyngeal and right submandibular lymph nodes are mildly enlarged.

COMPUTED TOMOGRAPHIC DIAGNOSIS

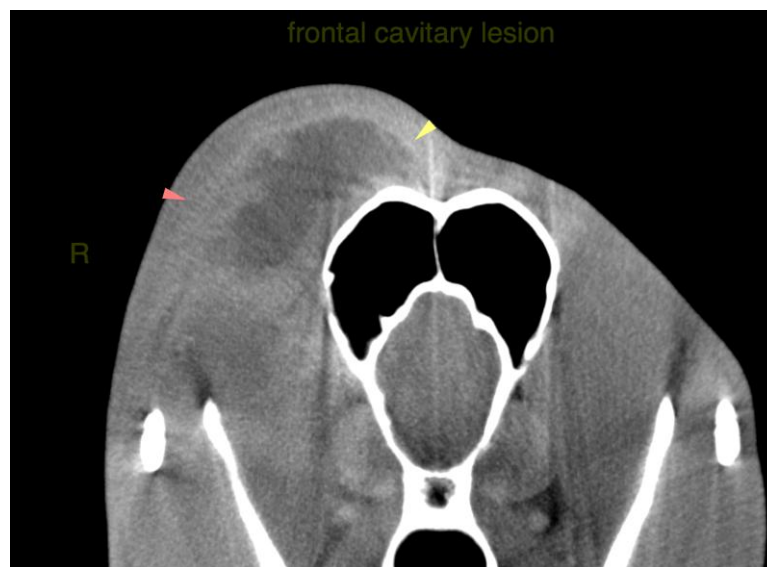
- Right frontal cavitory lesion with rim enhancement and temporal extension associated with regional soft tissue swelling and lymphadenopathy.

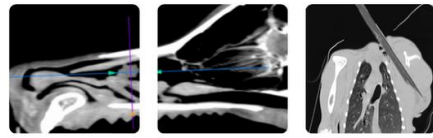
INTERPRETATION OF FINDINGS & FURTHER RECOMMENDATIONS

The CT study reveals a cavitory lesion in the right frontal and temporal region with peripheral rim enhancement and fluid filled center. Regional cellulitis and lymphadenitis are noted. The findings are highly suggestive for an abscess. Evidence of foreign material is not detected.

The regional lymph node changes are compatible with reactive lymphadenitis.

Surgical drainage and debridement should be considered if not performed already.





PATIENT

Archie Wilson

SPECIES

Canine

BREED

Cocker Spaniel

SEX

M

AGE

1Y, 2M

WEIGHT

15.4

INTERPRETED BY

Nele Eley (Ondreka),
DVM Dr. med. vet.,
DipECVDI

IMAGING PERFORMED BY

Patricia Sanchez
Sanchez

HOSPITAL NAME

Animal Trust - Bolton

REFERRING VET

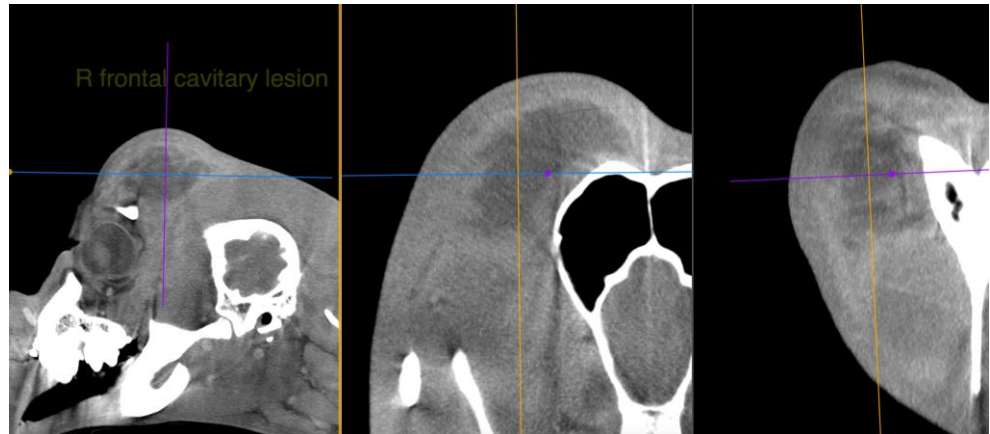
Patricia Sanchez Sanchez

INVOICE

72884

DATE

12-8-25



The information and recommendations provided are based on the images presented by the referring veterinarian. No evaluation can be communicated regarding pathology that was not visible in the image/video clips provided.

Thank you for this referral. If the clinical or image interpretation does not parallel your findings or if I can be of any further assistance please contact me.

Nele Eley (Ondreka), DVM, Dr. med. vet., DipECVDI
European Specialist in Veterinary Diagnostic Imaging, Cert. Radiology,
Senior lecturer University of Giessen/Germany, Veterinary Faculty, Department of Radiology.
info@sonopath.com