



**PATIENT**

Lia Suarez

**PRESENTING CLINICAL SIGNS**

Seizures, change in behavior and aggression (suspect secondary to Keppra)

**SPECIES**

Canine

**COMPUTED TOMOGRAPHIC STUDY OF THE HEAD**

Plain and post contrast studies available for review.

**BREED**

Boxer

**COMPUTED TOMOGRAPHIC FINDINGS**

Rightward shift of the cerebral falx is noted level with the frontal and temporal lobes of the brain suggesting potential for a mass effect within the left cerebral hemisphere. The attenuation is slightly irregular with a mild focal decrease in attenuation level with the left temporal lobe; however, this is superimposed by beam hardening artifacts.

**SEX**

Female Spayed

Thin and smoothly folded conchae and turbinates with even smooth mucosal lining.

Both temporomandibular joints present congruent joint spaces with even subchondral bone surfaces and are considered within normal limits.

**AGE**

11 Years

A moderate amount of fluid attenuating material is present within the left tympanic bulla. A mild amount of hypoattenuating material is seen within the medial aspect of the left external auditory meatus as well.

**INTERPRETED BY**

Nele Eley, DVM  
Dr. med. Vet. DipECVDI

The submandibular and medial retropharyngeal lymph nodes are small and elongated with a normal short-to-long-axis-ratio is < 0.5, the attenuation and contrast enhancement pattern is uniform.

The salivary glands present within normal limits.

**HOSPITAL NAME**

Mobile Pet Imaging

The visible dentition is within normal limits.

**COMPUTED TOMOGRAPHIC DIAGNOSIS**

- Suspect mass effect within the left cerebral hemisphere.
- Left sided otitis media and externa.

**REFERRING VET**

Meaux

**INTERPRETATION OF THE FINDINGS & FURTHER RECOMMENDATIONS**

The CT findings suggest presence of a mass effect within the left cerebral hemisphere. The origin of the mass effect remains unclear; however, intraaxial brain pathology such as neoplasia, cerebrovascular disease, and less likely inflammatory/infectious is considered likely based on the CT findings. Consider further definition by means of an MRI should the patient remain refractory to the initiated medical anticonvulsive treatment.

**INVOICE**

48900

**DATE**

12-8-21



**PATIENT**

Lia Suarez

**SPECIES**

Canine

**BREED**

Boxer

**SEX**

Female Spayed

**AGE**

11 Years

**INTERPRETED BY**

Nele Eley, DVM  
Dr. med. Vet. DipECVDI

**HOSPITAL NAME**

Mobile Pet Imaging

**REFERRING VET**

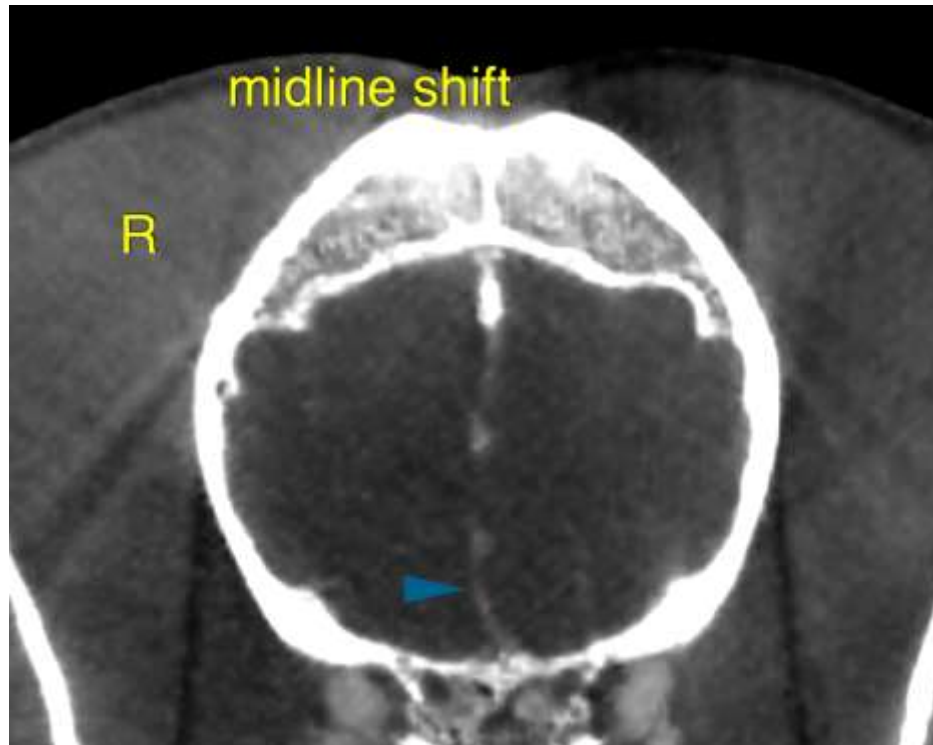
Meaux

**INVOICE**

48900

**DATE**

12-8-21



The information and recommendations provided are based on the images presented by the referring veterinarian. No evaluation can be communicated regarding pathology that was not visible in the image/video clips provided.

Thank you for this referral. If the clinical or image interpretation does not parallel your findings or if I can be of any further assistance please contact me.

**Nele Eley, DVM, Dr. med. vet., DipECVDI**  
European Specialist in Veterinary Diagnostic Imaging, Cert. Radiology,  
Senior lecturer University of Giessen, Germany, Veterinary Faculty, Department of Radiology  
Nele.Eley@sonopath.com