

**PATIENT**

Lady Iturralde

PRESENTING CLINICAL SIGNS

Hx of seizures that first started about 4 months ago. Frequency has increased recently (a few days ago the pet had several seizures).
Abnormal PE/Chem/CBC/UA Results: ALT 512

SPECIES

Canine

COMPUTED TOMOGRAPHIC STUDY OF THE HEAD

Plain and post contrast studies available for review.

BREED

Chihuahua

COMPUTED TOMOGRAPHIC FINDINGS

Skull sutures are not completely closed.

SEX

Female Spayed

Mild bilateral lateral ventriculomegaly is seen. There is no evidence of structural changes of the neuroparenchyma. No pathologic contrast enhancement is noted.

Thin and smoothly folded conchae and turbinates with even smooth mucosal lining.

Both temporomandibular joints present congruent joint spaces with even subchondral bone surfaces and are considered within normal limits.

AGE

10 Years

Both tympanic bullae are aerated, the mucosal lining is not seen, the bony wall is smooth and thin. The external auditory meatuses present within normal limits.

INTERPRETED BY

Nele Eley, DVM
Dr. med. Vet. DipECVDI

The submandibular and medial retropharyngeal lymph nodes are small and elongated with a normal short-to-long-axis-ratio is < 0.5 , the attenuation and contrast enhancement pattern is uniform.

The salivary glands present within normal limits.

HOSPITAL NAME

Mobile Pet Imaging

Mild periodontal disease with bone loss of the alveolar crest in the incisor portions of both maxilla and both mandibles is seen.

COMPUTED TOMOGRAPHIC DIAGNOSIS**REFERRING VET**

Meaux

- Mild ventriculomegaly.
- Structurally normal presentation of the brain.

INTERPRETATION OF THE FINDINGS & FURTHER RECOMMENDATIONS**INVOICE**

48899

No structural abnormality of the brain can be identified in the CT study. The mild enlargement of the lateral ventricles may well represent an anatomic variant of no clinical significance.

Complementary csf analysis could be considered in order to screen for nonstructural brain pathology including metabolic/toxic, inflammatory/infectious, neurodegenerative, and other.

DATE

12-8-21



PATIENT

Lady Iturralde

SPECIES

Canine

BREED

Chihuahua

SEX

Female Spayed

AGE

10 Years

INTERPRETED BY

Nele Eley, DVM
Dr. med. Vet. DipECVDI

HOSPITAL NAME

Mobile Pet Imaging

REFERRING VET

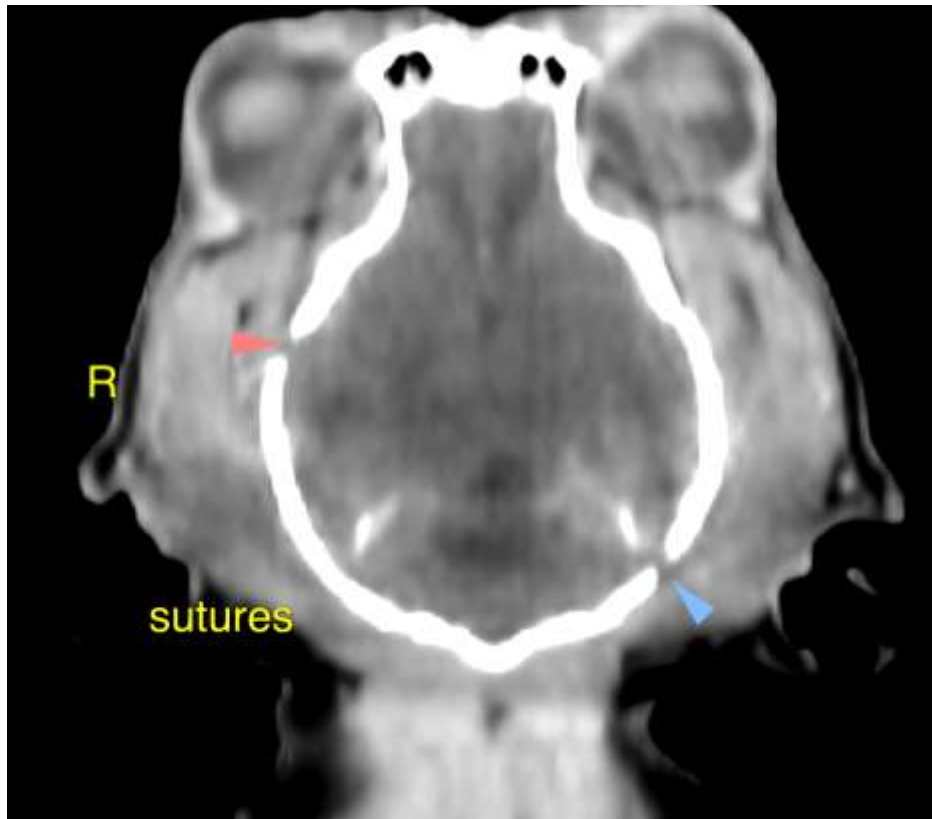
Meaux

INVOICE

48899

DATE

12-8-21



The information and recommendations provided are based on the images presented by the referring veterinarian. No evaluation can be communicated regarding pathology that was not visible in the image/video clips provided.

Thank you for this referral. If the clinical or image interpretation does not parallel your findings or if I can be of any further assistance please contact me.

Nele Eley, DVM, Dr. med. vet., DipECVDI
European Specialist in Veterinary Diagnostic Imaging, Cert. Radiology,
Senior lecturer University of Giessen, Germany, Veterinary Faculty, Department of Radiology
Nele.Eley@sonopath.com