



PATIENT

Hazel Groff

PRESENTING CLINICAL SIGNS

RH lameness. Suspect partial unstable CCL tear
Abnormal PE/Chem/CBC/UA Results: N/A

SPECIES

Canine

ULTRASONOGRAPHIC FINDINGS

Right Stifle

Synovial swelling and effusion are noted in the infrapatellar recess of the right stifle joint. There is heterogeneity with an overall increase in echogenicity of the infrapatellar fat pad. Regional synovial swelling is seen as well as a hypoechoic halo circumferential to the cranial cruciate ligament.

BREED

Pit X

SEX

FS

The cranial cruciate ligament is thick, irregularly delineated with echoarchitectural changes, and focal fiber disruption.

AGE

6 Years

ULTRASONOGRAPHIC DIAGNOSIS

- Synovialitis, effusion, and cranial cruciate ligament injury of the right stifle.

INTERPRETATION OF THE FINDINGS & FURTHER RECOMMENDATIONS

The ultrasonographic findings support the suspicion of partial rupture of the cranial cruciate ligament with concurrent synovialitis and effusion in the right stifle joint. Consider surgical intervention in order to address the presumed biomechanical instability and prevent further damage to the articular structures.

INTERPRETED BY

Nele Eley, DVM
Dr. med. Vet. DipECVDI

HOSPITAL NAME

Foxfield Veterinary
Services

REFERRING VET

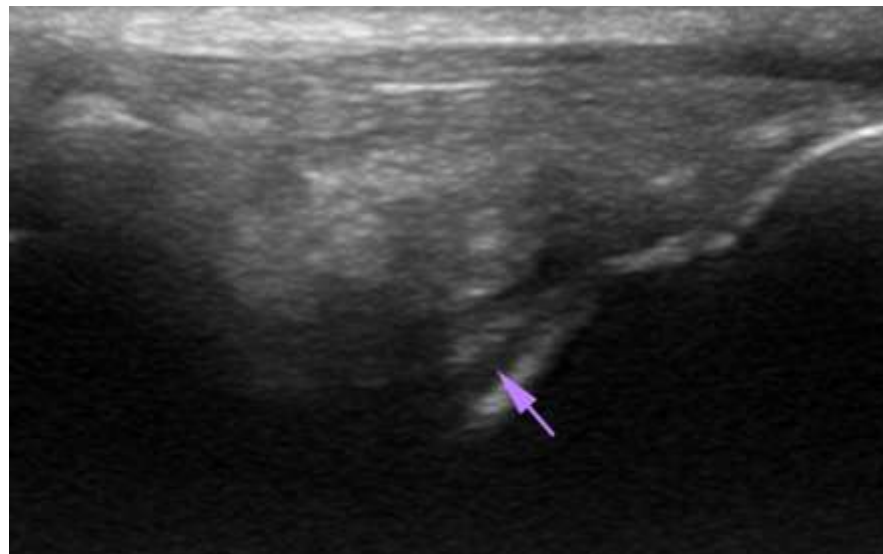
A.Rodriguez

INVOICE

48857

DATE

12-7-21





PATIENT

Hazel Groff

SPECIES

Canine

BREED

Pit X

SEX

FS

AGE

6 Years

INTERPRETED BY

Nele Eley, DVM
Dr. med. Vet. DipECVDI

HOSPITAL NAME

Foxfield Veterinary
Services

REFERRING VET

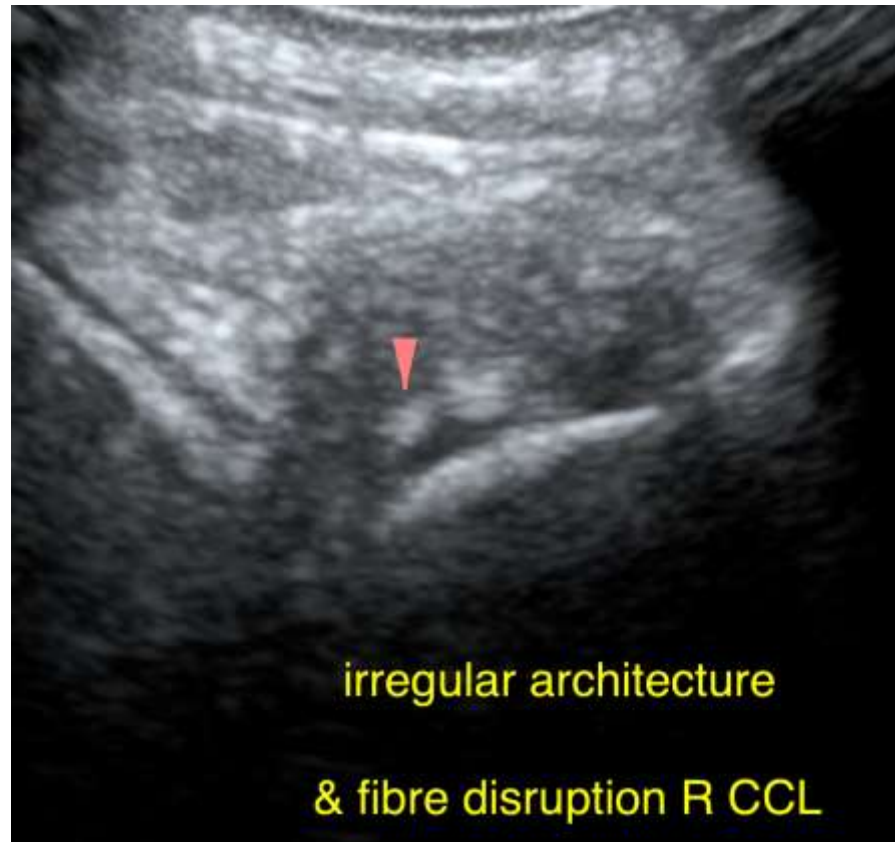
A.Rodriguez

INVOICE

48857

DATE

12-7-21



The information and recommendations provided are based on the images presented by the referring veterinarian. No evaluation can be communicated regarding pathology that was not visible in the image/video clips provided.

Thank you for this referral. If the clinical or image interpretation does not parallel your findings or if I can be of any further assistance please contact me.

Nele Eley, DVM, Dr. med. vet., DipECVDI
European Specialist in Veterinary Diagnostic Imaging, Cert. Radiology,
Senior lecturer University of Giessen, Germany, Veterinary Faculty, Department of Radiology
Nele.Eley@sonopath.com