



PATIENT

Blondie Fiorentino

PRESENTING CLINICAL SIGNS

Thyroid cancer w/ narrow but complete margins and no lymphatic or vascular invasion. Sx was in June 2021. Previous medical history: pyloric GIST tumor in June 2020, incomplete excision, June until Dec cyclophosphamide and Palladia, since Dec 2020 Palladia alone, clinically doing well since surgery, US every 3 months since surgery, appears in remission; CT for thoracic met check.

SPECIES

Canine

COMPUTED TOMOGRAPHIC STUDY OF THE THORAX

Plain and post contrast studies available for review.

BREED

Beagle

COMPUTED TOMOGRAPHIC FINDINGS

The bony structures are within normal limits.

SEX

Female Spayed

The sternal, cranial mediastinal and tracheobronchial lymph nodes are small elongated with a normal short-to-long-axis-ratio is < 0.5, the attenuation and contrast enhancement pattern are uniform and considered within normal limits.

The cardiovascular structures including the pulmonary vasculature are within normal limits.

AGE

9 Years

Mild redundancy of the dorsal tracheal ligament is seen.

Occasional pulmonary osteomas are noted. There is no evidence of interstitial pulmonary nodules or masses.

INTERPRETED BY

Nele Eley, DVM
Dr. med. Vet. DipECVDI

Small incidental gas pockets are seen within the esophageal lumen, there is no evidence of abnormal dilation.

The stomach is post-prandial but appears within normal limits.

HOSPITAL NAME

Mobile Pet Imaging

The kidneys are partially included, and occasional cortical infarcts are noted.

COMPUTED TOMOGRAPHIC DIAGNOSIS

REFERRING VET

Meaux

- No evidence of pulmonary metastatic disease.
- Normal age related lung.
- No evidence of mediastinal lymphadenomegaly.
- Cortical renal infarcts - incidental.
- Redundant dorsal tracheal ligament - typically incidental as well.

INVOICE

48846

INTERPRETATION OF THE FINDINGS & FURTHER RECOMMENDATIONS

The CT screening is negative for pulmonary metastatic disease. The findings of the lung and bronchial tree are considered within age related normal limits.

DATE

12-7-21



PATIENT

Blondie Fiorentino

SPECIES

Canine

BREED

Beagle

SEX

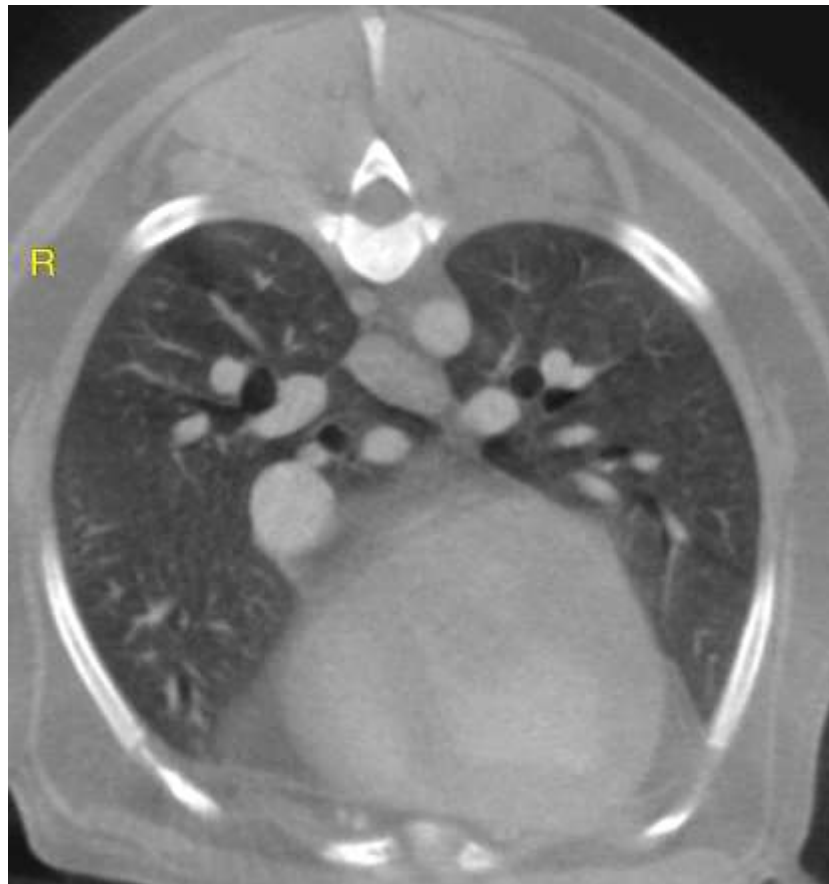
Female Spayed

AGE

9 Years

INTERPRETED BY

Nele Eley, DVM
Dr. med. Vet. DipECVDI



HOSPITAL NAME

Mobile Pet Imaging

REFERRING VET

Meaux

INVOICE

48846

DATE

12-7-21

The information and recommendations provided are based on the images presented by the referring veterinarian. No evaluation can be communicated regarding pathology that was not visible in the image/video clips provided.

Thank you for this referral. If the clinical or image interpretation does not parallel your findings or if I can be of any further assistance please contact me.

Nele Eley, DVM, Dr. med. vet., DipECVDI
European Specialist in Veterinary Diagnostic Imaging, Cert. Radiology,
Senior lecturer University of Giessen, Germany, Veterinary Faculty, Department of Radiology
Nele.Eley@sonopath.com