

**PATIENT**

Pilot Kaiser

PRESENTING CLINICAL SIGNS

Pet presented for CT to R/O hydrocephalus. Congenital cleft palate.

SPECIES

Canine

COMPUTED TOMOGRAPHIC STUDY OF THE HEAD

Plain and post contrast studies available for review.

BREED

French Bulldog

COMPUTED TOMOGRAPHIC FINDINGS

The patient is a brachycephalic head type with dome shaped calvarium and shortened facial bones.

Moderate to severe bilaterally symmetric dilation of the lateral ventricles is seen as well as dilation of the third ventricle of the brain.

SEX

MN

The volume of the tympanic bullae is small. The osseous lining is thick walled. The left tympanic bulla is filled with fluid attenuating material.

The hard and soft palate are not fused resulting in a long mid sagittal cleft.

AGE

2 Years

Mild bilateral nasal fluid accumulation is noted.

The naso- and oro- pharynx appear to be narrow.

INTERPRETED BYNele Eley, DVM
Dr. med. Vet. DipECVDI

There appears to be mild generalized swelling of the laryngeal soft tissues.

The tracheal lumen appears to be small.

COMPUTED TOMOGRAPHIC DIAGNOSIS

- Hydrocephalus internus.
- Congenital cleft palate with concurrent nondestructive rhinitis.
- Left sided otitis media - secondary to auditory tube stenosis.

HOSPITAL NAMEMobile Pet Imaging
CFL**INTERPRETATION OF THE FINDINGS & FURTHER RECOMMENDATIONS****REFERRING VET**

Borecky

The CT findings are compatible with hydrocephalus internus. The degree of ventricular dilation appears to be moderate to severe. The changes can be progressive in character and ventricular peritoneal shunting may be required. Clinical significance, however, with this degree of ventricular dilation is variable and clinical correlation is most important. In order to determine the presence of periventricular edema, or other signs of active distension, an MRI could be considered if indicated based on the presence of clinical signs.

INVOICE

48811

DATE

12-6-21



PATIENT

Pilot Kaiser

SPECIES

Canine

BREED

French Bulldog

SEX

MN

AGE

2 Years

INTERPRETED BY

Nele Eley, DVM
Dr. med. Vet. DipECVDI

HOSPITAL NAME

Mobile Pet Imaging
CFL

REFERRING VET

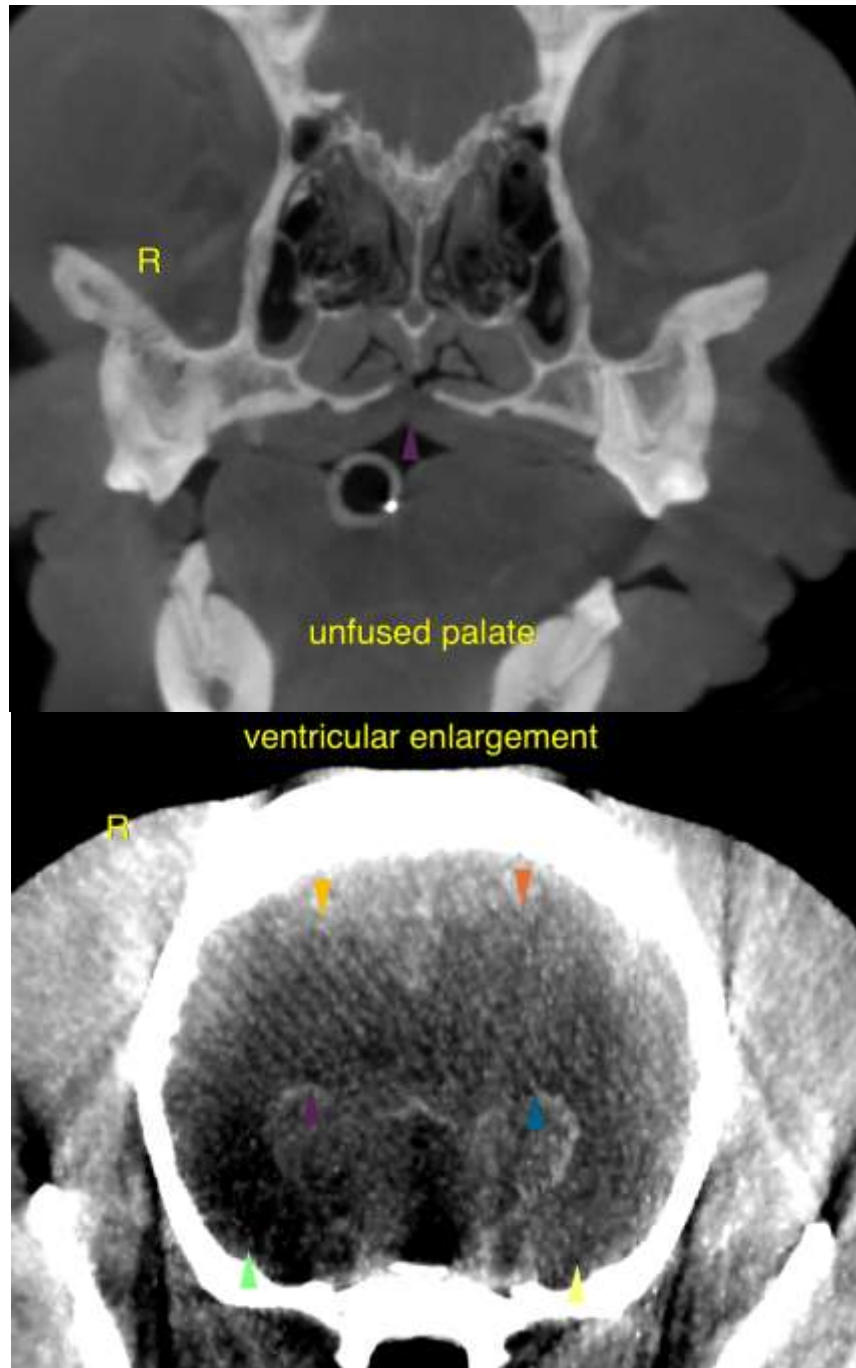
Borecky

INVOICE

48811

DATE

12-6-21





PATIENT

Pilot Kaiser

The information and recommendations provided are based on the images presented by the referring veterinarian. No evaluation can be communicated regarding pathology that was not visible in the image/video clips provided.

Thank you for this referral. If the clinical or image interpretation does not parallel your findings or if I can be of any further assistance please contact me.

SPECIES

Canine

Nele Eley, DVM, Dr. med. vet., DipECVDI
European Specialist in Veterinary Diagnostic Imaging, Cert. Radiology,
Senior lecturer University of Giessen, Germany, Veterinary Faculty, Department of Radiology
Nele.Eley@sonopath.com

BREED

French Bulldog

SEX

MN

AGE

2 Years

INTERPRETED BY

Nele Eley, DVM
Dr. med. Vet. DipECVDI

HOSPITAL NAME

Mobile Pet Imaging
CFL

REFERRING VET

Borecky

INVOICE

48811

DATE

12-6-21