



PATIENT

Oreo Robles

PRESENTING CLINICAL SIGNS

O want to recheck because pet still seems to be losing weight and has been very picky with his food, O tried switching his food but it did not help. drinking a little more water but O thinks it may be because he is mainly eating dry treats. vomiting last week but it stopped on Thursday.
 Abnormal PE/Chem/CBC/UA Results: Diag- ALT 115 FPL- Normal UA to lab via UG cysto- pending- explained to O if proteinuria will add UPC ratio

SPECIES

Feline

RADIOGRAPHIC STUDY OF THE THORAX & ABDOMEN

BREED

Right lateral and ventrodorsal views totaling 4 images available for review.

Domestic Medium Hair

RADIOGRAPHIC FINDINGS

Thorax

SEX

The surrounding bony structures are within normal limits.

MN

The heart is of normal size and shape and there is no evidence of cardiac chamber or vascular enlargement. The pulmonary vasculature is within normal limits.

AGE

8 Years

The cranial mediastinum presents the expected soft tissue opacity. The mediastinal width is less than twice the width of the vertebral column at the same level.

INTERPRETED BY

Nele Eley, DVM
 Dr. med. Vet. DipECVDI

The trachea is normal in diameter and presents the anticipated course. The luminal outline of the trachea is smooth.

The bronchial tree presents with thin walls and tapers uniformly towards the periphery as expected.

The lung parenchyma presents the expected architecture and opacity. The intrapulmonary vascular branching is seen up to the third order lung vessels.

HOSPITAL NAME

Animal Paradise Hospital

The diaphragm is well delineated with even surface and the expected mild cranial bulging of the diaphragmatic cupola.

Abdomen

REFERRING VET

Dr. Mostafa Elshafie

The surrounding bony structures are within normal limits.

No abnormalities of the extraabdominal soft tissues are noted. The abdominal wall is smooth and thin.

INVOICE

48825

The serosal detail is maintained throughout the peritoneal and retroperitoneal space.

The liver is appropriate in position, size and presents uniform opacity.

DATE

12-6-21

The splenic head is in the anticipated position and within normal limits for size and opacity. The splenic tail is not seen.



PATIENT

Oreo Robles

Both kidneys are seen and present with normal size, shape, delineation and opacity. The urinary bladder is in its anticipated position. No radiopaque calculi are noted throughout the upper and lower urinary tract.

The stomach is empty and nondilated.

SPECIES

Feline

The small intestinal loops are evenly distributed throughout the mid abdomen. Subjectively, there is the impression of mild generalized increase in small intestinal wall thickness. An occasional gas pattern is seen within the small intestine. No evidence of abnormal dilation, plication, or foreign material is noted.

BREED

Domestic Medium
Hair

The colon contains a moderate amount of inspissated fecal matter.

RADIOGRAPHIC DIAGNOSIS

- Small intestinal maldigestion pattern.

SEX

MN

INTERPRETATION OF THE FINDINGS & FURTHER RECOMMENDATIONS

The radiographic study reveals no evidence of mechanical ileus. Functional ileus is a potential. Owing to the longer standing clinical signs, further definition by means of ultrasound should be considered in order to rule out diffuse intestinal pathology and pathology such as pancreatopathy in correlation with the laboratory workup.

AGE

8 Years

INTERPRETED BY

Nele Eley, DVM
Dr. med. Vet. DipECVDI

HOSPITAL NAME

Animal Paradise
Hospital

REFERRING VET

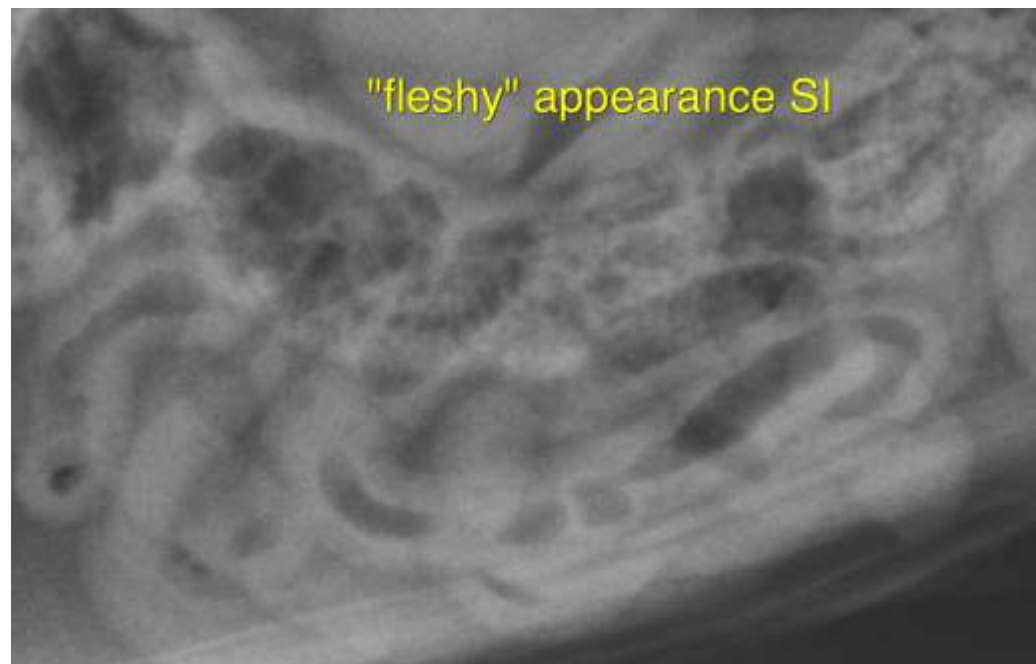
Dr. Mostafa Elshafie

INVOICE

48825

DATE

12-6-21





PATIENT

Oreo Robles

The information and recommendations provided are based on the images presented by the referring veterinarian. No evaluation can be communicated regarding pathology that was not visible in the image/video clips provided.

Thank you for this referral. If the clinical or image interpretation does not parallel your findings or if I can be of any further assistance please contact me.

SPECIES

Feline

Nele Eley, DVM, Dr. med. vet., DipECVDI
European Specialist in Veterinary Diagnostic Imaging, Cert. Radiology,
Senior lecturer University of Giessen, Germany, Veterinary Faculty, Department of Radiology
Nele.Eley@sonopath.com

BREED

Domestic Medium
Hair

SEX

MN

AGE

8 Years

INTERPRETED BY

Nele Eley, DVM
Dr. med. Vet. DipECVDI

HOSPITAL NAME

Animal Paradise
Hospital

REFERRING VET

Dr. Mostafa Elshafie

INVOICE

48825

DATE

12-6-21