


PATIENT PRESENTING CLINICAL SIGNS

Pablo Iyengar Vomiting 4-5 times last Saturday and has diarrhea, and not eating and drinking well. Owner said that he ate a small piece of dryer ball. Need to rule out possible obstruction or foreign body

SPECIES RADIOGRAPHIC STUDY OF THE ABDOMEN

Canine Right and left lateral and ventrodorsal views of the abdomen totaling 6 images available for review.

RADIOGRAPHIC FINDINGS
BREED

The surrounding bony structures are within normal limits.

Cavalier King
Charles Spaniel

No abnormalities of the extra-abdominal soft tissues are noted. The abdominal wall is smooth and thin.

The serosal detail is maintained throughout the peritoneal and retroperitoneal space.

SEX

The liver is appropriate in position and size and presents uniform opacity.

Neutered Male

The splenic head is in the anticipated position and within normal limits for size and opacity. The splenic body and tail are considered normal for position, size, shape, and opacity.

AGE

14 Months

Both kidneys are seen and present with normal size, shape, delineation, and opacity. The urinary bladder is in its anticipated position. No radiopaque calculi are noted throughout the upper and lower urinary tract.

INTERPRETED BY

Nele Eley (Ondreka),
DVM Dr. med. vet.,
DipECVDI

The stomach contains a mild amount of granulated soft tissue opaque material compatible with food. No evidence of abnormal dilation or radiopaque foreign material is seen. The colon and cecum contain mostly gas. A mild amount of fecal matter is seen within the transverse colon and cecum. The small intestinal loops are evenly distributed throughout the mid abdomen with no evidence of abnormal dilation, plication, or radiopaque foreign material.

RADIOGRAPHIC DIAGNOSIS
HOSPITAL NAME

Truscott AH

- Normal radiographic presentation of the abdomen without radiographic signs of mechanical ileus

INTERPRETATION OF FINDINGS & FURTHER RECOMMENDATIONS
REFERRING VET

Dr. Medhat Meawad

No radiographic evidence of obstructive ileus or radiopaque foreign material is found. Abdominal ultrasound could be considered in case of persisting or deteriorating clinical signs.

INVOICE

43221

DATE

12/5/22



PATIENT

Pablo Iyengar

SPECIES

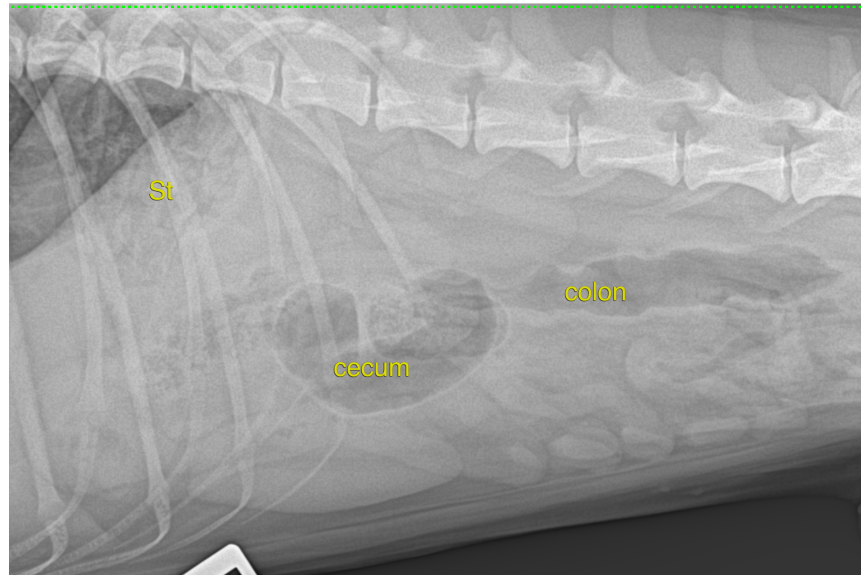
Canine

BREED

Cavalier King
Charles Spaniel

SEX

Neutered Male



AGE

14 Months

The information and recommendations provided are based on the images presented by the referring veterinarian. No evaluation can be communicated regarding pathology that was not visible in the image/video clips provided.

Thank you for this referral. If the clinical or image interpretation does not parallel your findings or if I can be of any further assistance please contact me.

INTERPRETED BY

Nele Eley (Ondreka),
DVM Dr. med. vet.,
DipECVDI

Nele Eley (Ondreka), DVM, Dr. med. vet., DipECVDI
European Specialist in Veterinary Diagnostic Imaging, Cert. Radiology,
Senior lecturer University of Giessen/Germany, Veterinary Faculty, Department of Radiology.
Nele.Eley@sonopath.com

HOSPITAL NAME

Truscott AH

REFERRING VET

Dr. Medhat Meawad

INVOICE

43221

DATE

12/5/22