

PATIENT PRESENTING CLINICAL SIGNS

Mystic Soto Mystic presented for evaluation of possible seizures. History of head pressing. This happened before during a stressful event, but then recurrent now during sleep.

SPECIES Abnormal PE/Chem/CBC/UA Results: CBC --- unremarkable CHEM --- BUN mild increased, ALT mild increased

Canine

COMPUTED TOMOGRAPHIC STUDY OF THE HEAD

BREED Plain and post-contrast studies available for review.

Dachshund **COMPUTED TOMOGRAPHIC FINDINGS**

Generalized atrophy of the masticatory muscles is seen. There is multifocal periodontal disease and an incomplete dentition accentuating the bilateral mandibular molar teeth.

SEX

Spayed Female

The brain parenchyma presents no evidence of deviation from its expected anatomy and symmetry. Attenuation and enhancement of the brain and meninges present within normal limits. Mild dilation of the lateral ventricles of the brain without evidence of active distention of the ventricular system is seen.

AGE

17 Years

The middle and inner ear present within normal limits.

COMPUTED TOMOGRAPHIC DIAGNOSIS

- Normal CT findings of the brain
- Mild ventriculomegaly without evidence of active distention

INTERPRETED BY

Nele Eley (Ondreka),
DVM Dr. med. vet.,
DipECVDI

INTERPRETATION OF FINDINGS & FURTHER RECOMMENDATIONS

The CT study does not reveal evidence of structural brain pathology. Mild ex vacuo dilation of the ventricular system of the brain is noted and most likely due to parenchymal atrophy. The atrophy may be within age related normal limits. However, dementia with cognitive dysfunction is one potential differential diagnosis. Other potential underlying causes of the clinical signs described in the history include cerebral microangiopathy, stroke, systemic/metabolic disease, and meningoencephalitis.

HOSPITAL NAME

Vet Image Center

REFERRING VET

Dr. J. Fernandez

INVOICE

43214

DATE

12/5/22



PATIENT

Mystic Soto

SPECIES

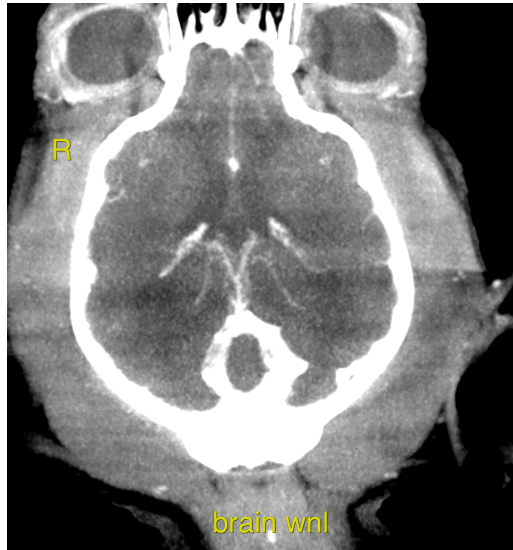
Canine

BREED

Dachshund

SEX

Spayed Female



AGE

17 Years

The information and recommendations provided are based on the images presented by the referring veterinarian. No evaluation can be communicated regarding pathology that was not visible in the image/video clips provided.

Thank you for this referral. If the clinical or image interpretation does not parallel your findings or if I can be of any further assistance please contact me.

INTERPRETED BY

Nele Eley (Ondreka),
DVM Dr. med. vet.,
DipECVDI

Nele Eley (Ondreka), DVM, Dr. med. vet., DipECVDI
European Specialist in Veterinary Diagnostic Imaging, Cert. Radiology,
Senior lecturer University of Giessen/Germany, Veterinary Faculty, Department of Radiology.
Nele.Eley@sonopath.com

HOSPITAL NAME

Vet Image Center

REFERRING VET

Dr. J. Fernandez

INVOICE

43214

DATE

12/5/22