
**PATIENT PRESENTING CLINICAL SIGNS**

Luna De Moya Has a history of coughing. Ultrasound, echo, and radiographs were all inconclusive regarding potential diaphragmatic hernia. Harsh lung sounds on physical exam. Tachypneic. Intermittent open-mouthed breathing.

**SPECIES**

Feline

Abnormal PE/Chem/CBC/UA Results: Elevated ALT

**COMPUTED TOMOGRAPHIC STUDY OF THE THORAX**
**BREED**

DSH

Plain and post-contrast studies available for review.

**COMPUTED TOMOGRAPHIC FINDINGS**

A defect is seen within the right hemidiaphragm. The defect appears to be at the mid level of the diaphragmatic cupola.

**SEX**

Spayed Female

Large amounts of abdominal fat, the entire spleen, part of the liver, and the gallbladder are seen in the right hemithorax.

**AGE**

1 Year

The right lung presents moderate collapse. The lung lobe margins are retracted from the thoracic wall. There is cardiac shift towards the left side. Moderate atelectatic changes of the left lung are seen.

The aforementioned abdominal viscera are displaced into the right hemithorax, but perfusion appears to be maintained. The stomach is in the abdomen at the time of the examination. A thymic remnant is seen.

**INTERPRETED BY**

Nele Eley (Ondreka),  
 DVM Dr. med. vet.,  
 DipECVDI

**COMPUTED TOMOGRAPHIC DIAGNOSIS**

- Diaphragmatic hernia with collapse of the spleen, gallbladder, and part of the liver, as well as omentum into the right hemithorax
- Partial pulmonary collapse and mediastinal shift

**HOSPITAL NAME**

Mobile Pet Imaging

**INTERPRETATION OF FINDINGS & FURTHER RECOMMENDATIONS**
**REFERRING VET**

Dr. Seraydar

The CT study confirms the presence of a diaphragmatic hernia. Congenital hernia or quiet traumatic hernia are possible. The spleen, gallbladder, and part of the liver as well as omentum are displaced into the right hemithorax at the time of the examination. The diaphragmatic defect is to the right of the midline and appears to be within the diaphragmatic cupola. No evidence of thoracic wall trauma.

**INVOICE**

43212

**DATE**

12/5/22



**PATIENT**

Luna De Moya

**SPECIES**

Feline

**BREED**

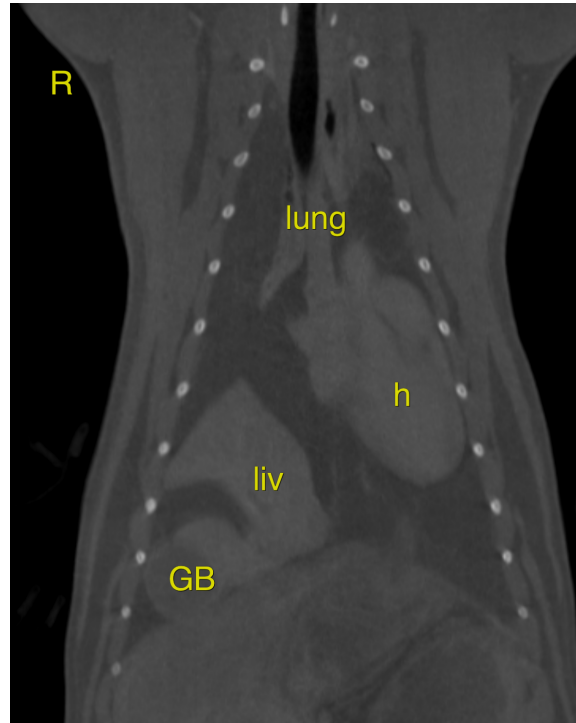
DSH

**SEX**

Spayed Female

**AGE**

1 Year



**INTERPRETED BY**

Nele Eley (Ondreka),  
DVM Dr. med. vet.,  
DipECVDI

**HOSPITAL NAME**

Mobile Pet Imaging

**REFERRING VET**

Dr. Seraydar

**The information and recommendations provided are based on the images presented by the referring veterinarian. No evaluation can be communicated regarding pathology that was not visible in the image/video clips provided.**

**INVOICE**

43212

**DATE**

12/5/22

Thank you for this referral. If the clinical or image interpretation does not parallel your findings or if I can be of any further assistance please contact me.

**Nele Eley (Ondreka)**, DVM, Dr. med. vet., DipECVDI  
European Specialist in Veterinary Diagnostic Imaging, Cert. Radiology,  
Senior lecturer University of Giessen/Germany, Veterinary Faculty, Department of Radiology.  
Nele.Eley@sonopath.com

