



PATIENT

Dixon Clausen

PRESENTING CLINICAL SIGNS

P was attacked by another dog 12/3/21
 Abnormal PE/Chem/CBC/UA Results: CBC- lymphocytes 0.59K/uL, eosinophils 0.01k/uL
 Chem+ electrolytes pending.

SPECIES

Canine

COMPUTED TOMOGRAPHIC STUDY OF THE HEAD

Plain study only available for review.

BREED

Chi Mix

COMPUTED TOMOGRAPHIC FINDINGS

Extensive soft tissue swelling on the dorsum of the nose and between the eyes is seen and can be traced throughout the dorsal curvature of the neurocranium.

SEX

Male

There is soft tissue emphysema in the right occipital and temporal area. Impression fracture of the neurocranium level with the right temporal bone is seen with ventral deviation of at least three larger sharply delineated bone splinters measuring approximately 10mm in length each. The bone splinters are deviated ventrally and cause impingement of the right cerebral hemisphere.

AGE

7 Years

There is a short oblique fracture of the coronoid process of the left mandibular ramus with peripheral soft tissue emphysema and soft tissue swelling.

INTERPRETED BY

Nele Eley, DVM
 Dr. med. Vet. DipECVDI

COMPUTED TOMOGRAPHIC DIAGNOSIS

- Open acute traumatic fractures of the neurocranium and left mandibular ramus secondary to bite injury with impingement of the right cerebral hemisphere.

INTERPRETATION OF THE FINDINGS & FURTHER RECOMMENDATIONS

HOSPITAL NAME

Wilvet Salem

The CT findings are compatible with acute traumatic osseous injury secondary to bite wounds. The fractures have to be considered infected and the impingement of the right cerebral hemisphere, secondary to the comminuted fractures of the neurocranium in the temporal area to the right of the midline, are significant.

REFERRING VET

Gardner

INVOICE

48782

DATE

12-4-21



PATIENT

Dixon Clausen

SPECIES

Canine

BREED

Chi Mix

SEX

Male

AGE

7 Years

INTERPRETED BY

Nele Eley, DVM
Dr. med. Vet. DipECVDI

HOSPITAL NAME

Wilvet Salem

REFERRING VET

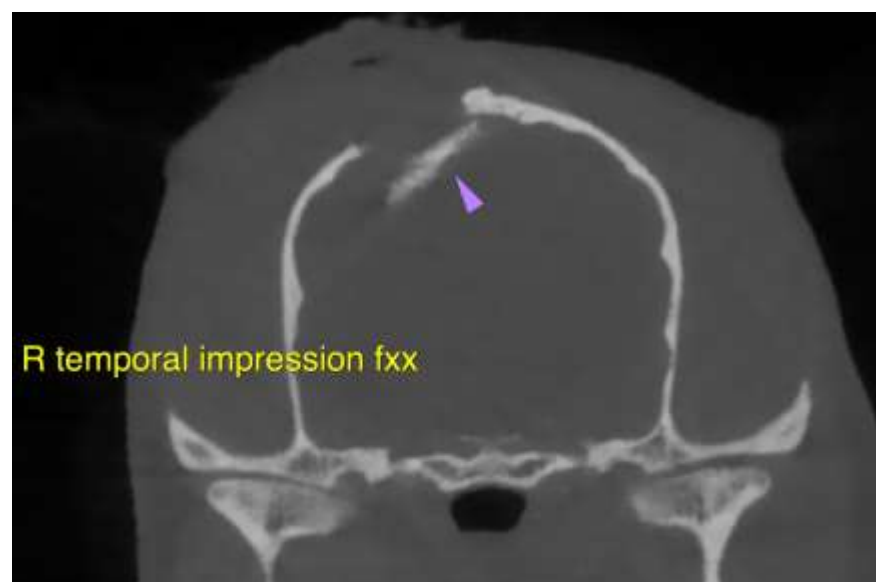
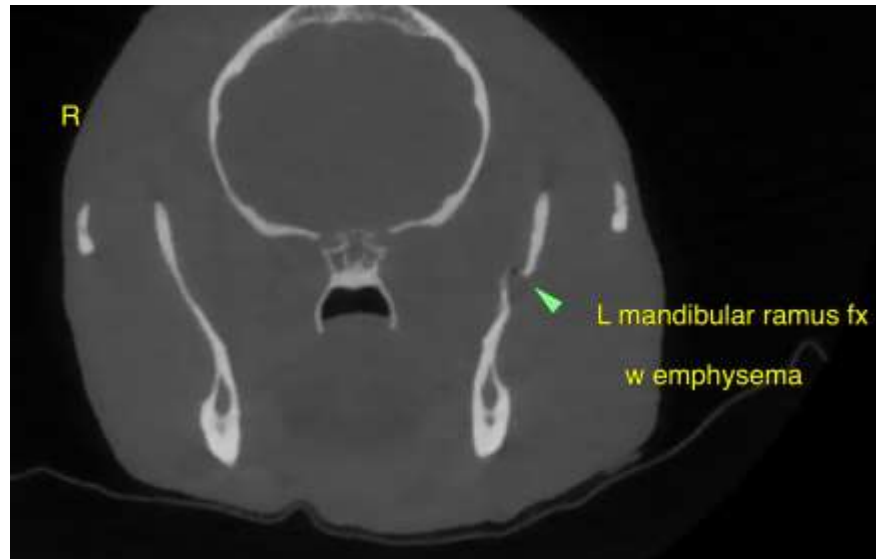
Gardner

INVOICE

48782

DATE

12-4-21





PATIENT

Dixon Clausen

SPECIES

Canine

BREED

Chi Mix

SEX

Male

AGE

7 Years

INTERPRETED BY

Nele Eley, DVM
Dr. med. Vet. DipECVDI

HOSPITAL NAME

Wilvet Salem

REFERRING VET

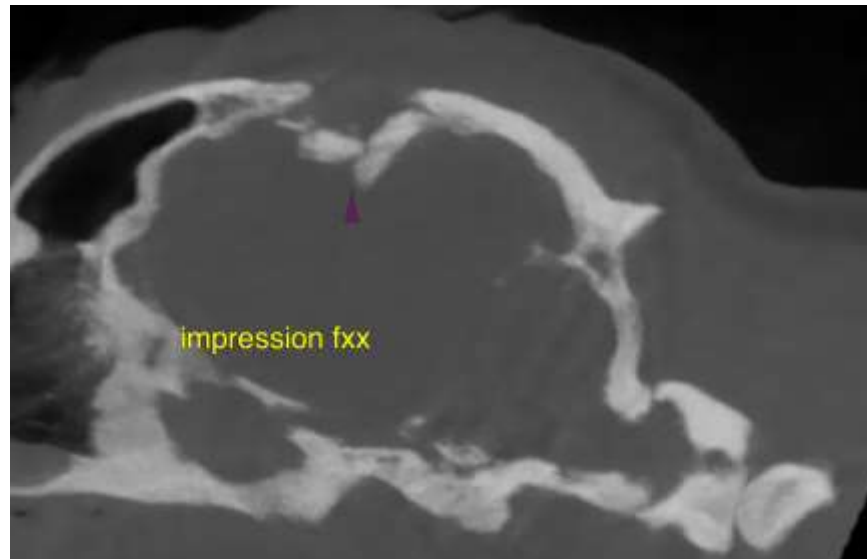
Gardner

INVOICE

48782

DATE

12-4-21



The information and recommendations provided are based on the images presented by the referring veterinarian. No evaluation can be communicated regarding pathology that was not visible in the image/video clips provided.

Thank you for this referral. If the clinical or image interpretation does not parallel your findings or if I can be of any further assistance please contact me.

Nele Eley, DVM, Dr. med. vet., DipECVDI
European Specialist in Veterinary Diagnostic Imaging, Cert. Radiology,
Senior lecturer University of Giessen, Germany, Veterinary Faculty, Department of Radiology
Nele.Eley@sonopath.com