

**PATIENT**Can Zeus Policia de  
PR**PRESENTING CLINICAL SIGNS**

Patient was presented for vaccines and 4dx. Owner had noticed his hip sway from side to side when he is working with the police department. Patient is weight bearing on all 4 limbs.  
Abnormal PE/Chem/CBC/UA Results: 4Dx: negative

**SPECIES**

Canine

**RADIOGRAPHIC STUDY OF THE LEFT STIFLE**

Mediolateral and craniocaudal views totaling 3 images available for review.

**BREED**

Belgian Malinois

**RADIOGRAPHIC FINDINGS**

There is a large expansile multicystic osteolytic lesion in the distal left femur accentuating the lateral metaphysis. Multifocal endosteal scalloping and cortical bone thinning are seen. Mixed moth-eaten and cystic lysis is noted. The transition zone to the unaffected bone is of moderate length and indistinct. Amorphous and spiculated periosteal new bone formation is seen in the caudal aspect of the distal left femur.

**SEX**

M

The left hind limb presents moderate loss of muscle volume.

Angular deformity of the tail is noted.

**AGE**

9 Years

**RADIOGRAPHIC DIAGNOSIS**

- Monostotic moderately aggressive osteolytic lesion of the distal left femur.
- Disuse atrophy of the left hind limb.

**INTERPRETED BY**Nele Eley, DVM  
Dr. med. Vet. DipECVDI**INTERPRETATION OF THE FINDINGS & FURTHER RECOMMENDATIONS**

The radiographic findings are compatible with monostotic aggressive osteolytic lesion. Primary neoplasia of bone such as osteosarcoma or chondrosarcoma is thought most likely; however, the radiographic presentation is not entirely typical. Giant cell tumor, lymphosarcoma, metastatic disease of another primary tumor, and aneurysmatic bone cyst cannot be ruled out as differential diagnoses and further definition by means of bone biopsy is strongly recommended along with staging, especially if the owner is interested in pursuing further treatment.

**HOSPITAL NAME**Paseos Veterinary  
Center**REFERRING VET**

Dr. M. Martes, DVM

**INVOICE**

48781

**DATE**

12-4-21



**PATIENT**

Can Zeus Policia de  
PR

**SPECIES**

Canine

**BREED**

Belgian Malinois

**SEX**

M

**AGE**

9 Years

**INTERPRETED BY**

Nele Eley, DVM  
Dr. med. Vet. DipECVDI

**HOSPITAL NAME**

Paseos Veterinary  
Center

**REFERRING VET**

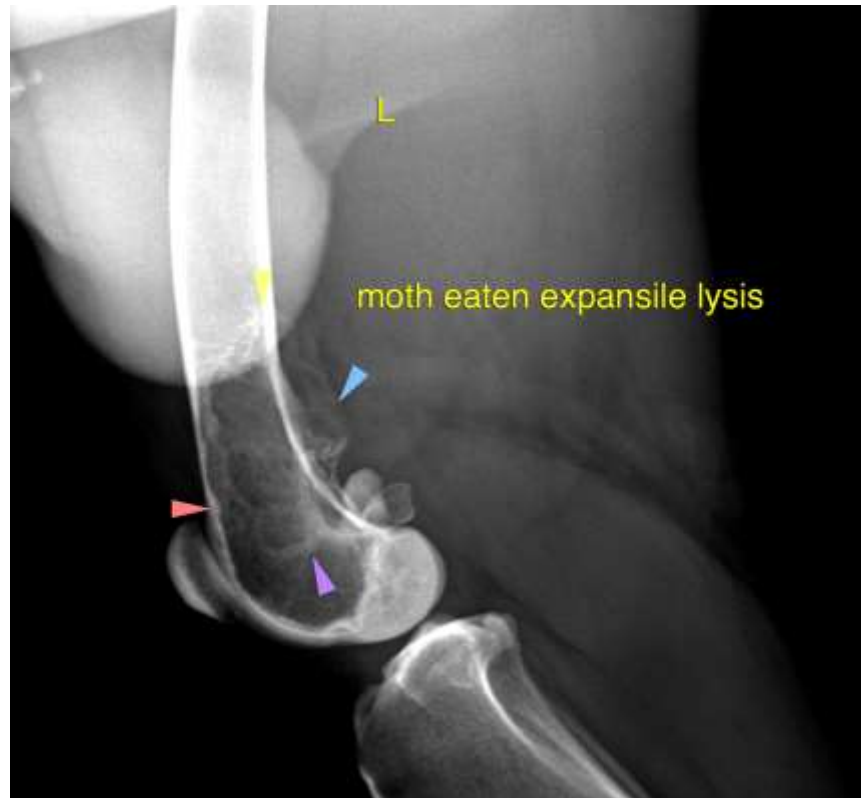
Dr. M. Martes, DVM

**INVOICE**

48781

**DATE**

12-4-21



The information and recommendations provided are based on the images presented by the referring veterinarian. No evaluation can be communicated regarding pathology that was not visible in the image/video clips provided.

Thank you for this referral. If the clinical or image interpretation does not parallel your findings or if I can be of any further assistance please contact me.

**Nele Eley**, DVM, Dr. med. vet., DipECVDI  
European Specialist in Veterinary Diagnostic Imaging, Cert. Radiology,  
Senior lecturer University of Giessen, Germany, Veterinary Faculty, Department of Radiology  
Nele.Eley@sonopath.com