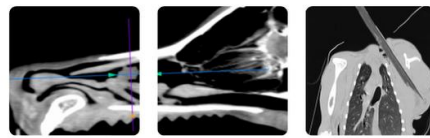




<b>PATIENT</b>	<b>PRESENTING CLINICAL SIGNS</b>
Byron Moss	Vomiting ++ painful abdomen. for a couple of days. Previously had intolerance to high fat food. on Ultrasound susp area seen. Stomach full with fluid even though regular vomit. intestines slightly dilated . Back in May Had a similar episode , had Biopsy taken - Clinical History: Gastrointestinal ileus. Exploratory laparotomy no evidence of mechanical obstruction, obtained biopsy of gastric wall full thickness before closure. INTERPRETATION Minimal to mild superficial lymphoplasmacytic gastritis with moderate to abundant Helicobacter.
<b>SPECIES</b>	
Canine	
<b>BREED</b>	Abnormal PE/Chem/CBC/UA Results: Catalyst Pancreatic Lipase 763 U/L ALT 142 U/L Amylase > 2,500 U/L Lipase 2,796 U/L
Miniature Dachshund	
<b>SEX</b>	<b>COMPUTED TOMOGRAPHIC STUDY OF THE ABDOMEN</b>
Male	Plain and post contrast studies are available for review.
<b>AGE</b>	<b>COMPUTED TOMOGRAPHIC FINDINGS</b>
1Y	The stomach contains moderate fluid content. No abnormal gastric dilation is seen. Mild diffuse gastric wall thickening is noted. The duodenum contains ingesta. Mild generalized duodenal wall thickening is noted. The remaining small intestines present within normal limits. No evidence of mechanical ileus, focal obstruction, or gastrointestinal foreign object is seen.
<b>WEIGHT</b>	The pancreas is normal in size, shape, and attenuation. No peripancreatic fat stranding or mass effect is identified.
9.2kg	
<b>INTERPRETED BY</b>	A right inguinal testicle is identified.
Nele Eley (Ondreka), DVM Dr. med. vet., DipECVDI	Mild symmetric prostatic enlargement is noted.
<b>IMAGING PERFORMED BY</b>	Both kidneys present within normal limits for size, shape and organ architecture. After contrast administration, a bilaterally symmetric and uniform nephro- and pyelogram is noted.
Hollie Sharp	Both liver and spleen present with normal shape, even surface, uniformly attenuating parenchyma and homogeneous contrast enhancement, unremarkable.
<b>HOSPITAL NAME</b>	There is no free abdominal fluid.
Animal Trust - Ellesmere Port	<b>COMPUTED TOMOGRAPHIC DIAGNOSIS</b>
<b>REFERRING VET</b>	<ul style="list-style-type: none"><li>• No CT evidence of mechanical gastrointestinal obstruction or foreign body.</li><li>• Mild gastroduodenal wall thickening consistent with inflammatory gastroduodenal disease.</li><li>• Fluid filled stomach without dilation compatible with functional ileus or delayed gastric emptying.</li><li>• Normal CT appearance of the pancreas.</li><li>• Right inguinal testicle (cryptorchism).</li><li>• Mild benign prostatic hyperplasia.</li></ul>
Dylan Payne	
<b>INVOICE</b>	<b>INTERPRETATION OF FINDINGS &amp; FURTHER RECOMMENDATIONS</b>
73141	The CT findings do not demonstrate a mechanical cause for the patient's acute vomiting and abdominal pain. The combination of fluid filled but nondilated stomach, mild intestinal distension, and mild gastroduodenal wall thickening is most consistent with functional gastrointestinal ileus likely secondary to inflammatory gastric or proximal intestinal disease, which appears to conform the prior
<b>DATE</b>	
12-31-25	



## PATIENT

Byron Moss

## SPECIES

Canine

## BREED

Miniature Dachshund

## SEX

Male

## AGE

1Y

## WEIGHT

9.2kg

## INTERPRETED BY

Nele Eley (Ondreka),  
DVM Dr. med. vet.,  
DipECVDI

## IMAGING PERFORMED BY

Hollie Sharp

## HOSPITAL NAME

Animal Trust -  
Ellesmere Port

## REFERRING VET

Dylan Payne

## INVOICE

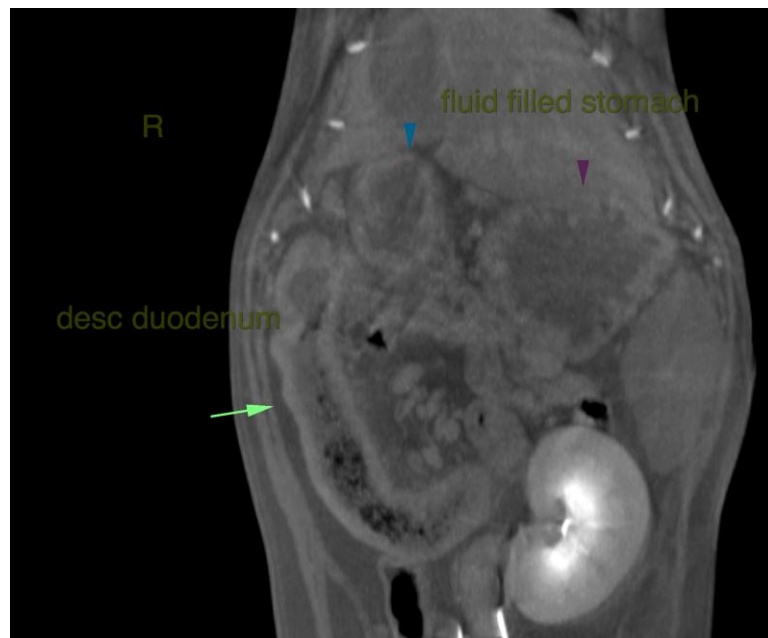
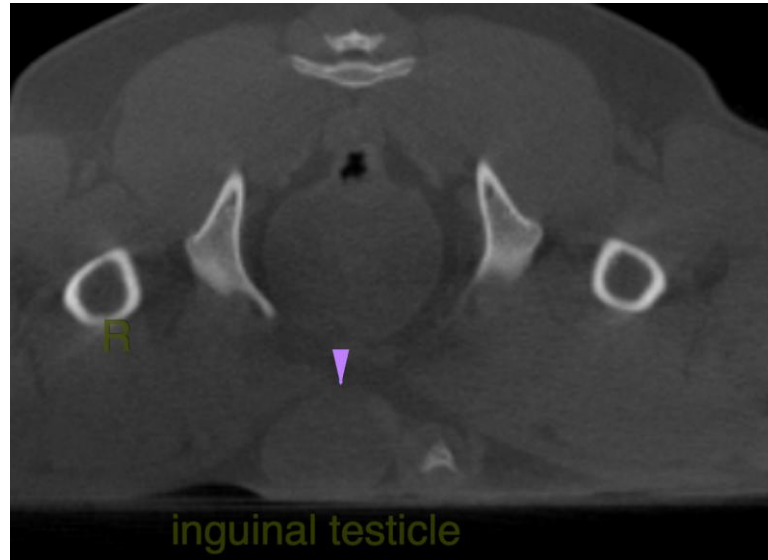
73141

## DATE

12-31-25

histopathologic diagnosis of lymphoplasmacytic gastritis with *Helicobacter* species. Recurrence or progression of chronic inflammatory gastroduodenal disease appears to be a strong consideration. Dietary fat intolerance may further exacerbate gastric motility disturbances.

Pancreatitis is considered unlikely based on CT appearance, though early or mild pancreatitis cannot be entirely excluded.





## PATIENT

Byron Moss

## SPECIES

Canine

## BREED

Miniature Dachshund

## SEX

Male

## AGE

1Y

## WEIGHT

9.2kg

## INTERPRETED BY

Nele Eley (Ondreka),  
DVM Dr. med. vet.,  
DipECVDI

## IMAGING PERFORMED BY

Hollie Sharp

## HOSPITAL NAME

Animal Trust -  
Ellesmere Port

## REFERRING VET

Dylan Payne

## INVOICE

73141

## DATE

12-31-25

The information and recommendations provided are based on the images presented by the referring veterinarian. No evaluation can be communicated regarding pathology that was not visible in the image/video clips provided.

Thank you for this referral. If the clinical or image interpretation does not parallel your findings or if I can be of any further assistance please contact me.

**Nele Eley (Ondreka)**, DVM, Dr. med. vet., DipECVDI

European Specialist in Veterinary Diagnostic Imaging, Cert. Radiology,  
Senior lecturer University of Giessen/Germany, Veterinary Faculty, Department of Radiology.

[info@sonopath.com](mailto:info@sonopath.com)