



## PATIENT

Millie Chalker

## SPECIES

Canine

## BREED

German Shepherd

## SEX

FS

## AGE

6Y

## WEIGHT

30.18

## INTERPRETED BY

Nele Eley (Ondreka),  
DVM Dr. med. vet.,  
DipECVDI

## IMAGING PERFORMED BY

Dr Trudeau

## HOSPITAL NAME

Vetcetera Animal  
Hospital

## REFERRING VET

Dr Trudeau

## INVOICE

73148

## DATE

12-30-25

## PRESENTING CLINICAL SIGNS

Previous ultrasound #64487; 4-18-2024; still having ongoing lameness issues; x-rays performed today as well; both achilles AUS

Abnormal PE/Chem/CBC/UA Results: Nov 2025 - NSF CBC/Chem and negative 4Dx

## ULTRASONOGRAPHIC FINDINGS

### Right Achilles Tendon Complex

The tendon fibers of the right achilles tendon complex are well organized and uniformly hyperechoic with normal fibular pattern. The superficial digital flexor tendon, gastrocnemius tendon, and deep tendon components are normal. The myotendinous junction is normal in echotexture and contour. Calcaneal bone surface appears normal. No bony irregularities or enthesiophytes are seen. There is no regional fluid accumulation. No significant distension of the calcaneal bursa is noted.

### Left Achilles Tendon Complex

The tendon fibers of the left achilles tendon complex are well organized and uniformly hyperechoic with normal fibrillar pattern. The superficial digital flexor tendon, gastrocnemius tendon, and deep tendon components are normal. The myotendinous junction is normal in echotexture and contour. Calcaneal bone surface appears normal. No bony irregularities or enthesiophytes are seen. There is no regional fluid accumulation. No significant distension of the calcaneal bursa is noted.

## ULTRASONOGRAPHIC DIAGNOSIS

- Normal ultrasonographic presentation of bilateral achilles tendon complexes.

## INTERPRETATION OF FINDINGS & FURTHER RECOMMENDATIONS

The ultrasonographic study of the achilles tendons reveals normal anatomic relationships with no evidence of tendinopathy, partial or complete tear, calcaneal pathology, or myotendinous injury. The persistent lameness may have contributing sources elsewhere including stifle, tarsus, hip, soft tissue injury, or neurologic disease. Correlation with the obtained radiographs and clinical examination findings is recommended.



## PATIENT

Millie Chalker

## SPECIES

Canine

## BREED

German Shepherd

## SEX

FS

## AGE

6Y

## WEIGHT

30.18

## INTERPRETED BY

Nele Eley (Ondreka),  
DVM Dr. med. vet.,  
DipECVDI

## IMAGING PERFORMED BY

Dr Trudeau

## HOSPITAL NAME

Vetcetera Animal  
Hospital

## REFERRING VET

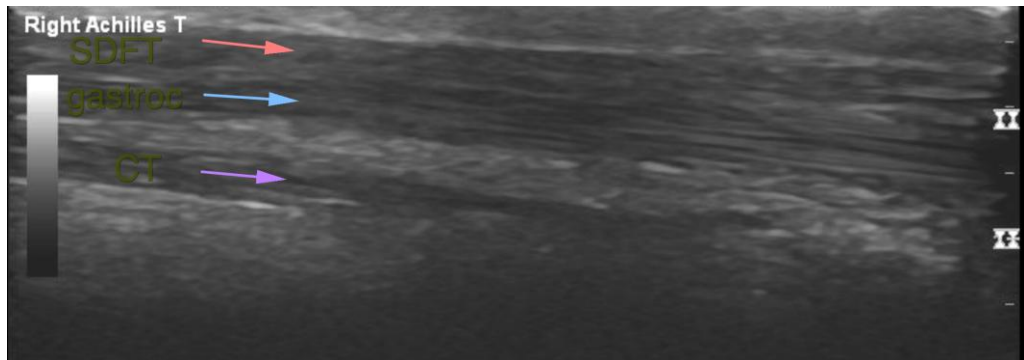
Dr Trudeau

## INVOICE

73148

## DATE

12-30-25



The information and recommendations provided are based on the images presented by the referring veterinarian. No evaluation can be communicated regarding pathology that was not visible in the image/video clips provided.

Thank you for this referral. If the clinical or image interpretation does not parallel your findings or if I can be of any further assistance please contact me.

**Nele Eley (Ondreka)**, DVM, Dr. med. vet., DipECVDI

European Specialist in Veterinary Diagnostic Imaging, Cert. Radiology,

Senior lecturer University of Giessen/Germany, Veterinary Faculty, Department of Radiology.

[info@sonopath.com](mailto:info@sonopath.com)