



PATIENT

Cali Wyckoff

SPECIES

Dog

BREED

Border Collie

SEX

FS

AGE

13Y

WEIGHT

43.4lbs

INTERPRETED BY

Nele Eley (Ondreka),
DVM Dr. med. vet.,
DipECVDI

IMAGING PERFORMED BY

Taylor Chasteen

HOSPITAL NAME

Pine Creek Veterinary
Hospital

REFERRING VET

Taylor Chasteen

INVOICE

72845

DATE

12-3-25

PRESENTING CLINICAL SIGNS

Right submandibular (suspect salivary gland) markedly enlarged, left prescapular lymph node/popliteal LNs slightly enlarged? may be patient's normal

Abnormal PE/Chem/CBC/UA Results: Biopsy results of salivary gland mass reveal salivary adenocarcinoma. Slide 1 (salivary mass): Fragments examined are composed nearly entirely of neoplastic cells forming a multinodular mass. Cells are cuboidal to polygonal and arranged in acini to packets along a fine fibrovascular stroma. Cells have indistinct borders and moderate amounts of eosinophilic granular cytoplasm with occasional clear vacuoles. Nuclei are ovoid with finely stippled chromatin and a single, round, basophilic nucleolus. Mitoses are 6 in 10 HPF (400x). There is mild anisocytosis and anisokaryosis. Multiple foci of necrosis disrupt the mass. In one section, there is a profound scirrhous response effacing adjacent adipose and connective tissue. Neoplastic cells extend to fragment margins.

COMPUTED TOMOGRAPHIC STUDY OF THE NECK

Post contrast studies of the neck are available for review.

COMPUTED TOMOGRAPHIC FINDINGS

The mandibles appear normal.

The mandibular salivary glands appear normal. Parotid salivary glands are also normal in size and morphology.

A 9mm sized, thick walled, cystic lesion is seen cranial to the mandibular salivary gland and ventral to the parotid salivary gland which may be post-procedural or residual.

The submandibular lymph nodes and retropharyngeal lymph nodes are normal in size and morphology.

The prescapular lymph nodes are within normal limits in size and morphology as well.

The left tympanic bulla contains fluid with osseous wall thickening consistent with otitis media.

Note soft tissues of the right side of the neck and face are partially cut off limiting complete assessment.

COMPUTED TOMOGRAPHIC DIAGNOSIS

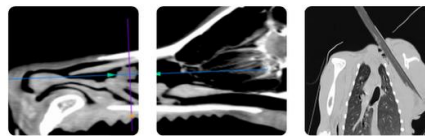
- Post-surgical changes or small residual lesion with cystic appearance cranial to the right mandibular salivary gland.
- No evidence of metastatic lymphadenopathy in the submandibular, retropharyngeal, and prescapular lymph nodes.
- Left bulla changes consistent with chronic otitis media – clinical correlation recommended.

INTERPRETATION OF FINDINGS & FURTHER RECOMMENDATIONS

The CT study reveals a small thick walled cystic lesion cranial to the right mandibular salivary gland which may be associated with the gland. The lesion may represent post-surgical changes from prior biopsy or residual tissue of a cystic or soft tissue lesion associated with the salivary gland.

The submandibular, retropharyngeal, and prescapular lymph nodes present within normal limits.

Note the presence of left sided otitis media.



PATIENT

Cali Wyckoff

SPECIES

Dog

BREED

Border Collie

SEX

FS

AGE

13Y

WEIGHT

43.4lbs

INTERPRETED BY

Nele Eley (Ondreka),
DVM Dr. med. vet.,
DipECVDI

IMAGING PERFORMED BY

Taylor Chasteen

HOSPITAL NAME

Pine Creek Veterinary
Hospital

REFERRING VET

Taylor Chasteen

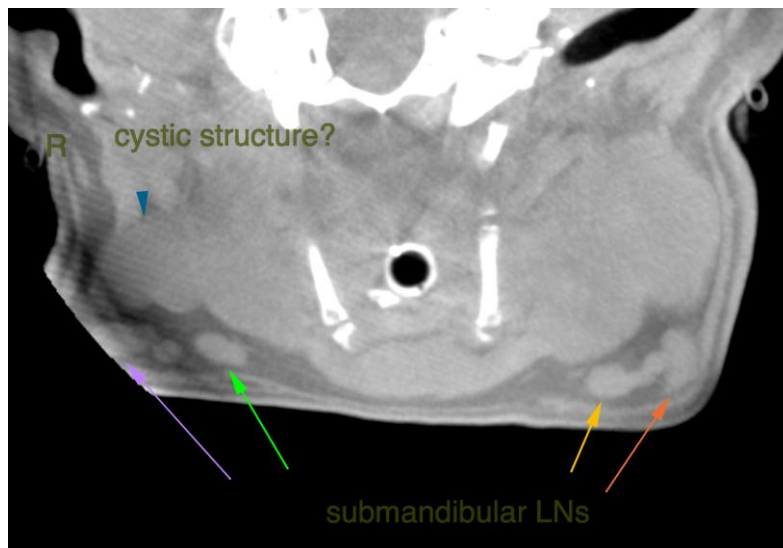
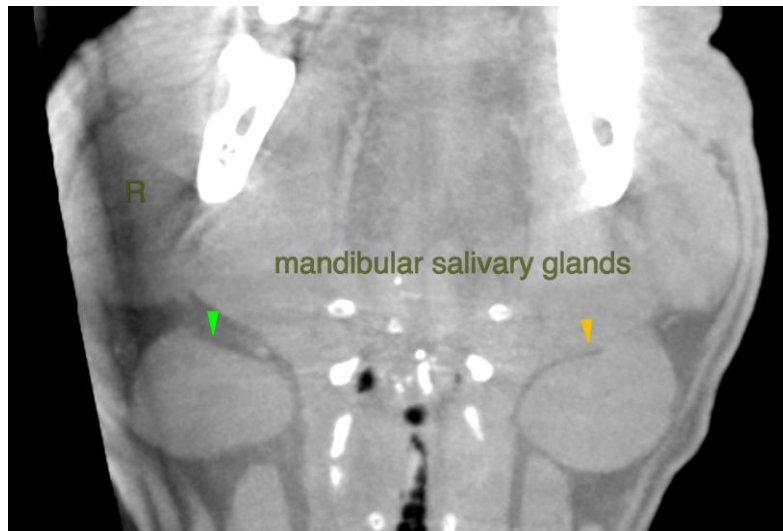
INVOICE

72845

DATE

12-3-25

Clinical correlation with biopsy and prior surgery findings is recommended. Clinical and CT monitoring of the surgery site can be considered.



The information and recommendations provided are based on the images presented by the referring veterinarian. No evaluation can be communicated regarding pathology that was not visible in the image/video clips provided.

Thank you for this referral. If the clinical or image interpretation does not parallel your findings or if I can be of any further assistance please contact me.

Nele Eley (Ondreka), DVM, Dr. med. vet., DipECVDI
European Specialist in Veterinary Diagnostic Imaging, Cert. Radiology,
Senior lecturer in University of Giessen/Germany, Veterinary Faculty, Department of Radiology.
info@sonopath.com