
PATIENT PRESENTING CLINICAL SIGNS

Toby Vocaturro patient was presented today for recheck from cough per owner his cough is better than before he started prednison 10 mg twice daily for 2 weeks and now he is down to once daily had xray done month ago and owner would like to compare xray of today to the previous one eating and drinking normal

SPECIES

Canine

RADIOGRAPHIC STUDY OF THE THORAX

7 images include right and left lateral and ventrodorsal views of the thorax, compared to prior study dated 11/5/22.

BREED

Labrador Retriever

RADIOGRAPHIC FINDINGS

The degree of pulmonary inflation is moderate. A moderate generalized residual bronchial lung pattern is noted with even distribution throughout the lung. There is no evidence of residual alveolar or interstitial infiltrates in the cranioventral lung.

SEX

Neutered Male

The sternal lymph nodes are not seen. There is no evidence of abnormal mediastinal widening.

AGE

8 Years

Course and width of the trachea are within normal limits. The mild esophageal aerophagia is considered within normal limits as well.

The radiographic presentation of the cardiac silhouette is within normal limits. Vertebral heart score is 10.0. there is no evidence of specific chamber enlargement. The thoracic boundaries present within age related normal limits.

INTERPRETED BY

Nele Eley (Ondreka),
 DVM Dr. med. vet.,
 DipECVDI

RADIOGRAPHIC DIAGNOSIS

- Resolved alveolar lung pattern and residual bronchial lung pattern

INTERPRETATION OF FINDINGS & FURTHER RECOMMENDATIONS
HOSPITAL NAME

Central Jersey AH

The radiographic study reveals no evidence of alveolar or interstitial infiltrates. The cranioventral lung has cleared, and a residual generalized bronchial lung pattern is noted, which represents lower airway disease. Based on the clinical history and the response to the anti-allergic treatment, eosinophilic bronchopneumopathy is considered more likely than infectious bronchitis, even though this cannot be determined radiographically of course.

REFERRING VET

Dr. Gabriel

INVOICE

43196

DATE

12/3/22



PATIENT

Toby Vocaturo

SPECIES

Canine

BREED

Labrador Retriever

SEX

Neutered Male

AGE

8 Years

INTERPRETED BY

Nele Eley (Ondreka),
DVM Dr. med. vet.,
DipECVDI

HOSPITAL NAME

Central Jersey AH

REFERRING VET

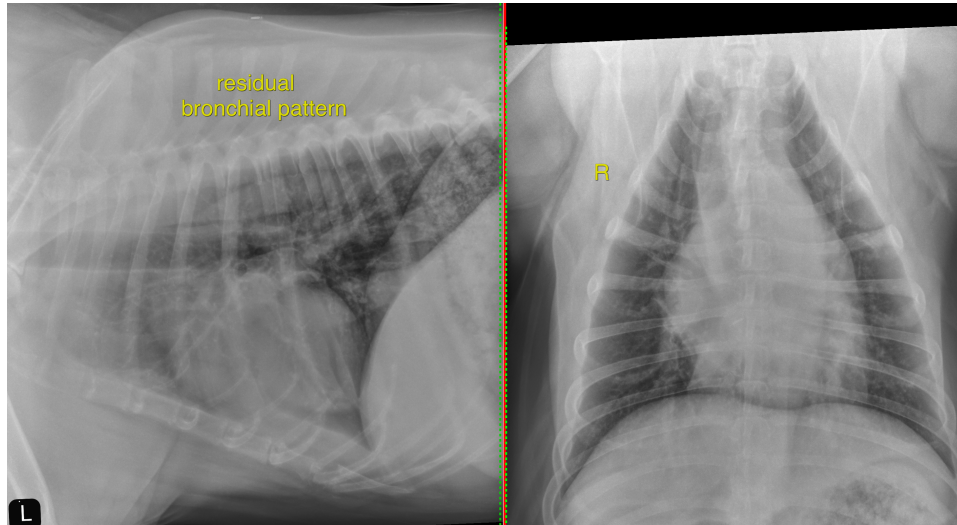
Dr. Gabriel

INVOICE

43196

DATE

12/3/22



The information and recommendations provided are based on the images presented by the referring veterinarian. No evaluation can be communicated regarding pathology that was not visible in the image/video clips provided.

Thank you for this referral. If the clinical or image interpretation does not parallel your findings or if I can be of any further assistance please contact me.

Nele Eley (Ondreka), DVM, Dr. med. vet., DipECVDI
European Specialist in Veterinary Diagnostic Imaging, Cert. Radiology,
Senior lecturer University of Giessen/Germany, Veterinary Faculty, Department of Radiology.
Nele.Eley@sonopath.com