



PATIENT

Olivia Motta

PRESENTING CLINICAL SIGNS

Pain on hip extension left side, intermittent limping

SPECIES

Canine

RADIOGRAPHIC STUDY OF THE PELVIS

Lateral and ventrodorsal views of the pelvis totaling 7 images available for review.

BREED

Daschund

RADIOGRAPHIC FINDINGS

Severe atrophy of the left hind limb musculature is seen.

SEX

Female

There is widening of the left coxofemoral joint space with a malshaped and small femoral head. An area of geographic osteolysis is seen in the proximal aspect of the left femoral head and surrounded by thin peripheral sclerosis. The proximal contour of the femoral head is flattened. Coarse trabecular bone pattern is noted within the left femoral diaphysis. The compact bone of the left femur and tibia is thin compared with the right side.

AGE

9 Months

RADIOGRAPHIC DIAGNOSIS

- Suspect aseptic necrosis of the left femoral head with disuse atrophy of the musculature and bones in the left hind limb.

INTERPRETATION OF THE FINDINGS & FURTHER RECOMMENDATIONS

The radiographic findings are compatible with Legg–Calvé–Perthes which described spontaneous devascularization and aseptic necrosis of the femoral head during skeletal maturation. Collapse of the femoral head and painful arthritis are the consequence which are associated with chronic disuse of the hind limb. Femoral head ostectomy is typically performed and proves curative in many small breed dogs.

INTERPRETED BY

Nele Eley, DVM
Dr. med. Vet. DipECVDI

HOSPITAL NAME

Sunset Animal
Hospital

REFERRING VET

Cristina Polit

INVOICE

55891

DATE

12-29-22



PATIENT

Olivia Motta

SPECIES

Canine

BREED

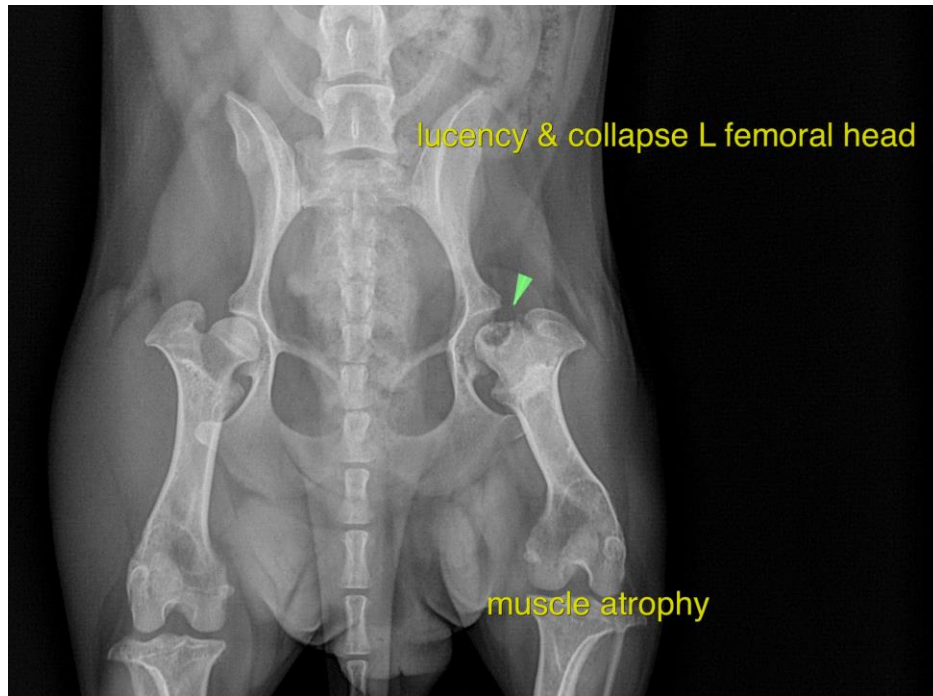
Daschund

SEX

Female

AGE

9 Months



INTERPRETED BY

Nele Eley, DVM
Dr. med. Vet. DipECVDI

The information and recommendations provided are based on the images presented by the referring veterinarian/sonographer. No evaluation can be communicated regarding pathology that was not visible in the image/video clips provided.

Thank you for this referral. If the clinical or image interpretation does not parallel your findings or if I can be of any further assistance please contact me.

HOSPITAL NAME

Sunset Animal
Hospital

Nele Eley, DVM, Dr. med. vet., DipECVDI
European Specialist in Veterinary Diagnostic Imaging, Cert. Radiology,
Senior lecturer University of Giessen, Germany, Veterinary Faculty, Department of Radiology
Nele.Eley@sonopath.com

REFERRING VET

Cristina Polit

INVOICE

55891

DATE

12-29-22