

**PATIENT**

Xena Gagnon Griffith

PRESENTING CLINICAL SIGNS

Vomited 3x today since morning. Vomited when fed breakfast this morning and vomited 3-4x yesterday. Has been eating and vomiting it out (1-2 hrs after)

SPECIES

Canine

RADIOGRAPHIC STUDY OF THE ABDOMEN

Multiple right lateral, left lateral, and ventrodorsal views totaling 6 images available for review.

BREED

American Bulldog Mix

RADIOGRAPHIC FINDINGS

The patient is mildly obese.

SEX

Spayed Female

The abdominal serosal detail is maintained.

AGE

4 Years

A long wound up thin metal opaque wire-type structure is contained within the stomach. A moderate amount of food or other granulated soft tissue opaque material is seen in the stomach as well. The wire-type structure does not appear to extend into the gastric outlet or duodenum at this point.

The small intestinal loops are turgid in appearance with gas content yet there is no evidence of abnormal dilation, plication, or radiopaque foreign material within the small intestine seen.

INTERPRETED BY

Nele Eley, DVM
Dr. med. Vet. DipECVDI

The large intestine contains a mild amount of fecal matter.

RADIOGRAPHIC DIAGNOSIS

- Wire-type gastric foreign material.
- No evidence of small intestinal ileus.

HOSPITAL NAME

Truscott Animal
Hospital

INTERPRETATION OF THE FINDINGS & FURTHER RECOMMENDATIONS

Foreign material appears to be contained within the stomach at the time of the radiographic study. However, it cannot be ruled out that nonradiopaque extensions of the foreign material or other attached foreign material are present and have progressed into the small intestine at this point. A careful attempt of endoscopic removal of the foreign material can be made after ensuring the foreign material is still within the stomach by means of recheck radiographs immediately prior to the procedure.

REFERRING VET

Medhat Meawad

INVOICE

49305

DATE

12-29-21



PATIENT

Xena Gagnon Griffith

SPECIES

Canine

BREED

American Bulldog Mix

SEX

Spayed Female

AGE

4 Years

INTERPRETED BY

Nele Eley, DVM
Dr. med. Vet. DipECVDI

HOSPITAL NAME

Truscott Animal
Hospital

REFERRING VET

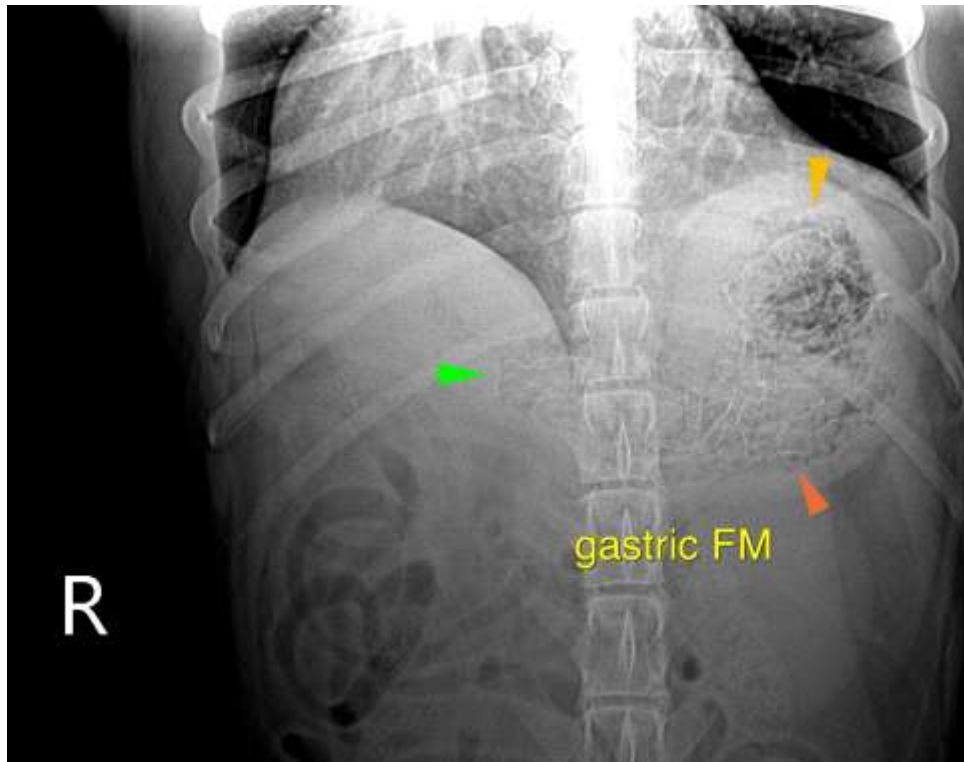
Medhat Meawad

INVOICE

49305

DATE

12-29-21



The information and recommendations provided are based on the images presented by the referring veterinarian. No evaluation can be communicated regarding pathology that was not visible in the image/video clips provided.

Thank you for this referral. If the clinical or image interpretation does not parallel your findings or if I can be of any further assistance please contact me.

Nele Eley, DVM, Dr. med. vet., DipECVDI
European Specialist in Veterinary Diagnostic Imaging, Cert. Radiology,
Senior lecturer University of Giessen, Germany, Veterinary Faculty, Department of Radiology
Nele.Eley@sonopath.com