

**PATIENT**

Charlie Drake

**PRESENTING CLINICAL SIGNS**

Reason for Xrays: History of Grade 3 Heart Murmur parasternal, recently started coughing.  
Current Meds: Percorten V 20 mgs q 4 weeks, Pred. 2.5 mgs Q.O.D.  
Abnormal PE/Chem/CBC/UA Results: CBC/CHEM: Normal

**SPECIES**

Canine

**RADIOGRAPHIC STUDY OF THE THORAX**

Left lateral and ventrodorsal views totaling 2 images available for review.

**BREED**

Poodle Mix

**RADIOGRAPHIC FINDINGS**

The patient is obese.

At least one nodular subcutaneous fat opaque mass is seen in the right axillary region.

**SEX**

Abundance of subcutaneous mediastinal and pericardial fat appears to be present.

**MN**

The vertebral heart score is 11.5 with mild elevation of the trachea and mild left atrial tenting.  
The pulmonary veins appear to be mildly congested. No evidence of cardiogenic pulmonary edema is seen.

**AGE**

11 Years

Course and width of the trachea are considered within normal limits. Presentation of the pulmonary parenchyma and bronchial tree is considered within age related normal limits.

**INTERPRETED BY**

Nele Eley, DVM  
Dr. med. Vet. DipECVDI

Mild generalized hepatomegaly is noted.

**RADIOGRAPHIC DIAGNOSIS**

- Mild left sided cardiomegaly with mild left atrial tenting - no evidence of congestive heart failure.
- Normal age related lung.
- Mild hepatomegaly.
- Thoracic wall lipoma.

**HOSPITAL NAME**

Byram Animal  
Hospital

**INTERPRETATION OF THE FINDINGS & FURTHER RECOMMENDATIONS****REFERRING VET**

Dr. Carlos Abdul-  
Chani

The radiographic findings of the cardiac silhouette suggest mild left ventricular and left atrial enlargement which may explain the patient's coughing by the potential mass effect of the left atrium onto the left mainstem bronchus. No evidence of decompensation is noted at this point; however, a more detailed assessment would require a cardiac echo. No structural cause for the clinical signs is identified in the lung and bronchial tree.

**INVOICE**

49294

The mild hepatomegaly may reflect steroid induced hepatopathy. Other metabolic or endocrine hepatopathy and diffuse infiltrative diseases are possible but less likely differential diagnoses.

**DATE**

12-29-21



**PATIENT**

Charlie Drake

**SPECIES**

Canine

**BREED**

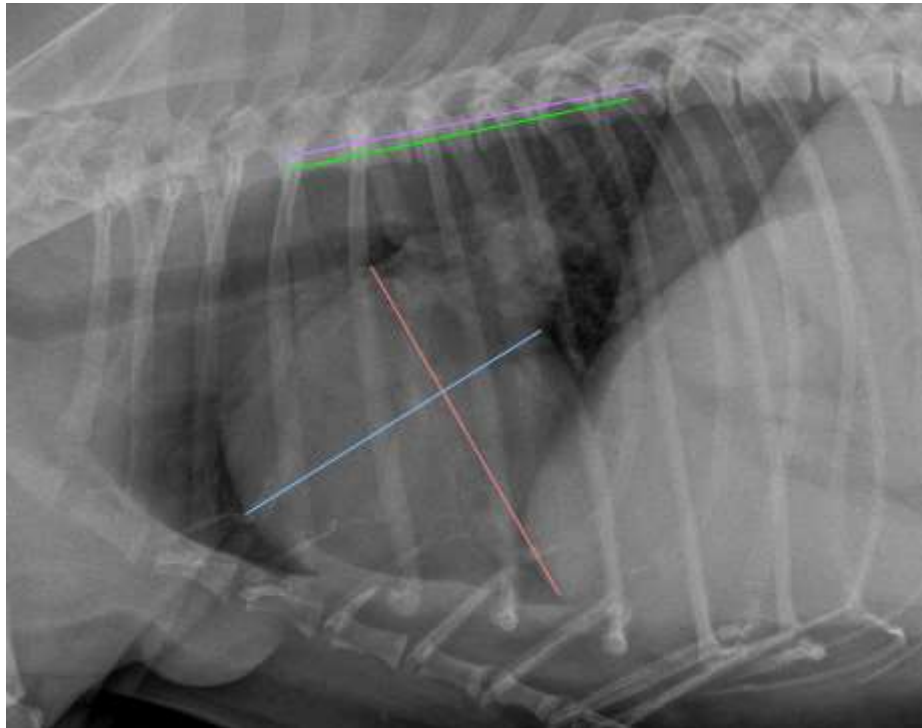
Poodle Mix

**SEX**

MN

**AGE**

11 Years



**INTERPRETED BY**

Nele Eley, DVM  
Dr. med. Vet. DipECVDI

The information and recommendations provided are based on the images presented by the referring veterinarian. No evaluation can be communicated regarding pathology that was not visible in the image/video clips provided.

Thank you for this referral. If the clinical or image interpretation does not parallel your findings or if I can be of any further assistance please contact me.

**HOSPITAL NAME**

Byram Animal  
Hospital

**Nele Eley**, DVM, Dr. med. vet., DipECVDI  
European Specialist in Veterinary Diagnostic Imaging, Cert. Radiology,  
Senior lecturer University of Giessen, Germany, Veterinary Faculty, Department of Radiology  
Nele.Eley@sonopath.com

**REFERRING VET**

Dr. Carlos Abdul-  
Chani

**INVOICE**

49294

**DATE**

12-29-21