



PATIENT

Bertie Gregor

PRESENTING CLINICAL SIGNS

Acute RPL lameness, toe touching. Negative cranial drawer and negative tibial thrust.

SPECIES

Canine

RADIOGRAPHIC STUDY OF THE STIFLES

Mediolateral and craniocaudal views of both stifles and ventrodorsal hip extended view of the pelvis totaling 4 images available for review.

Interpretation of the stifle region requested.

BREED

German Shepherd

RADIOGRAPHIC FINDINGS

Right Stifle

SEX

MN

Mild articular swelling level with the femoral tibial joint is seen. There is mild osseous remodeling of the periarticular margins such as the distal pole of the patella, lateral aspect of the femoral trochlea, and lateral aspect of the proximal tibia. No cranial thrust of the tibia is seen. The popliteal sesamoid bone is in its anticipated position. The fabellae present within normal limits. The patella ligament is thin and smoothly delineated.

AGE

5.5 Years

Left Stifle

The radiographic presentation of the left stifle is within normal limits.

INTERPRETED BY

Nele Eley, DVM
Dr. med. Vet. DipECVDI

There are radiographic changes of the coxofemoral joints which are not part of this interpretation.

RADIOGRAPHIC DIAGNOSIS

- Unspecific mild articular swelling of the right stifle with radiographic evidence of early degenerative joint disease.

HOSPITAL NAME

Tahoe Integrative
Veterinary Care

INTERPRETATION OF THE FINDINGS & FURTHER RECOMMENDATIONS

Mild articular swelling of the right stifle joint is noted which may reflect articular effusion, synovial swelling, or a combination of these. There also is evidence of early degenerative joint disease. Differential diagnosis includes cranial cruciate ligament injury such as early partial rupture and less likely meniscopathy. Since the occurrence of isolated meniscal injury is rare, trauma effusion and arthritis including immune mediated cannot be ruled out entirely. Correlate with the clinical palpation and consider aspiration and analysis of synovia and/or further articular imaging such as ultrasound or MRI for further definition.

REFERRING VET

Dr. Amanda Stuart

INVOICE

49312

DATE

12-29-21



PATIENT

Bertie Gregor

SPECIES

Canine

BREED

German Shepherd

SEX

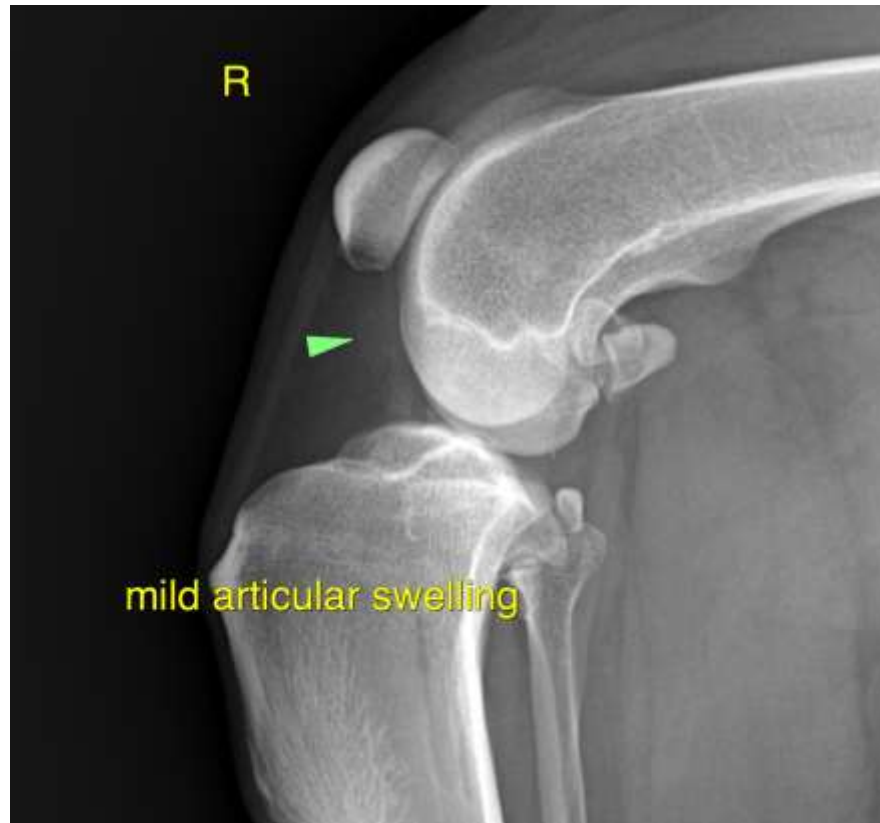
MN

AGE

5.5 Years

INTERPRETED BY

Nele Eley, DVM
Dr. med. Vet. DipECVDI



HOSPITAL NAME

Tahoe Integrative
Veterinary Care

REFERRING VET

Dr. Amanda Stuart

INVOICE

49312

DATE

12-29-21

The information and recommendations provided are based on the images presented by the referring veterinarian. No evaluation can be communicated regarding pathology that was not visible in the image/video clips provided.

Thank you for this referral. If the clinical or image interpretation does not parallel your findings or if I can be of any further assistance please contact me.

Nele Eley, DVM, Dr. med. vet., DipECVDI
European Specialist in Veterinary Diagnostic Imaging, Cert. Radiology,
Senior lecturer University of Giessen, Germany, Veterinary Faculty, Department of Radiology
Nele.Eley@sonopath.com