



PATIENT PRESENTING CLINICAL SIGNS

Woody Kloss Patient started licking Right hind paw on November first. He was seen at rdvm and they found some draining tracts and foreign material. His foot was not healing and he was still licking at his paw. They took him to another rdvm and they explored the site (Interdigital RPL between D3/D4) twice with out finding anything. He went for a recheck yesterday because his paw was still bothering him. They vet pressed on his foot blood and purulent material came from the top of his foot. rdvm rec. a CT to look for any additional material they could not find
 Abnormal PE/Chem/CBC/UA Results: WNL, purulent d/c and blood from both dorsal and palmar aspect of the interdigital web between 3rd and 4th digit

BREED COMPUTED TOMOGRAPHIC STUDY OF THE HIND PAWS

Labradoodle Plain and post contrast studies available for review.

SEX COMPUTED TOMOGRAPHIC FINDINGS

MN Soft tissue swelling is noted between the 3rd and 4th digits of the right hind paw with a contrast enhancing tract with peripheral rim enhancement and fluid attenuating center, which is arranged within the soft tissue between the 3rd and 4th digits in a dorsopalmar direction. A millimeter sized hyperattenuating structure is seen centrally within this tract. There is no evidence of concurrent osseous changes.

AGE COMPUTED TOMOGRAPHIC DIAGNOSIS

1

- Interdigital drainage tract with peripheral cellulitis and suspect organic foreign material between the 3rd and 4th digits in the right hind paw.

INTERPRETED BY

Nele Eley, DVM
 Dr. med. Vet. DipECVDI

INTERPRETATION OF THE FINDINGS & FURTHER RECOMMENDATIONS

HOSPITAL NAME

Wilvet Salem

The CT findings suggest presence of a small hyperattenuating millimeter sized structure in the area of the drainage tract between the 3rd and 4th digits, which is likely to represent residuals of organic foreign material. Fibrosis and developing dystrophic mineralization are potential but less likely differential diagnoses.

REFERRING VET

Dr. Dan Lewer

INVOICE

55883

DATE

12-28-22



PATIENT

Woody Kloss

SPECIES

Canine

BREED

Labradoodle

SEX

MN

AGE

1

INTERPRETED BY

Nele Eley, DVM
Dr. med. Vet. DipECVDI

HOSPITAL NAME

Wilvet Salem

REFERRING VET

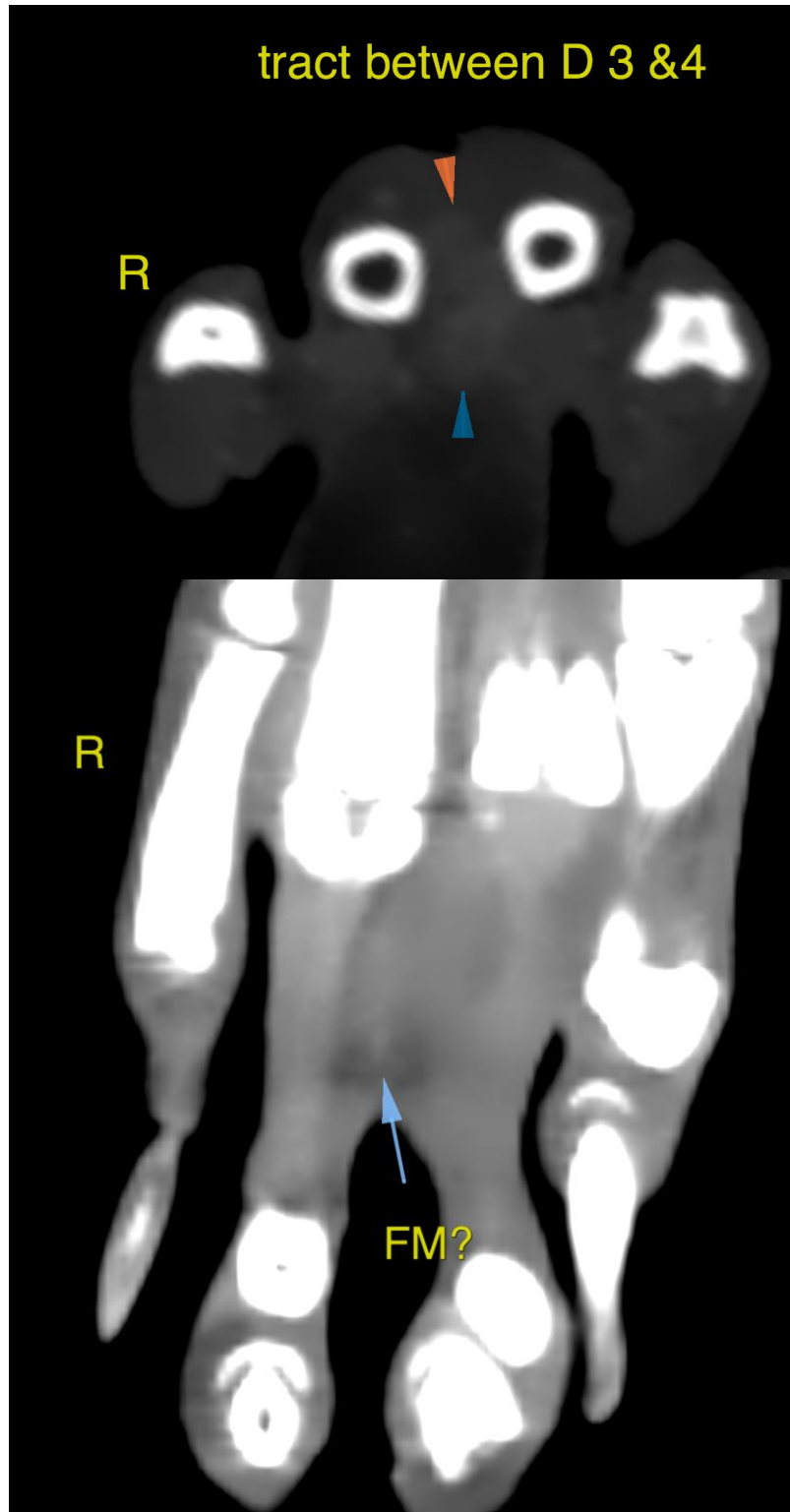
Dr. Dan Lewer

INVOICE

55883

DATE

12-28-22





PATIENT

Woody Kloss

SPECIES

Canine

BREED

Labradoodle

SEX

MN

AGE

1

INTERPRETED BY

Nele Eley, DVM
Dr. med. Vet. DipECVDI

HOSPITAL NAME

Wilvet Salem

REFERRING VET

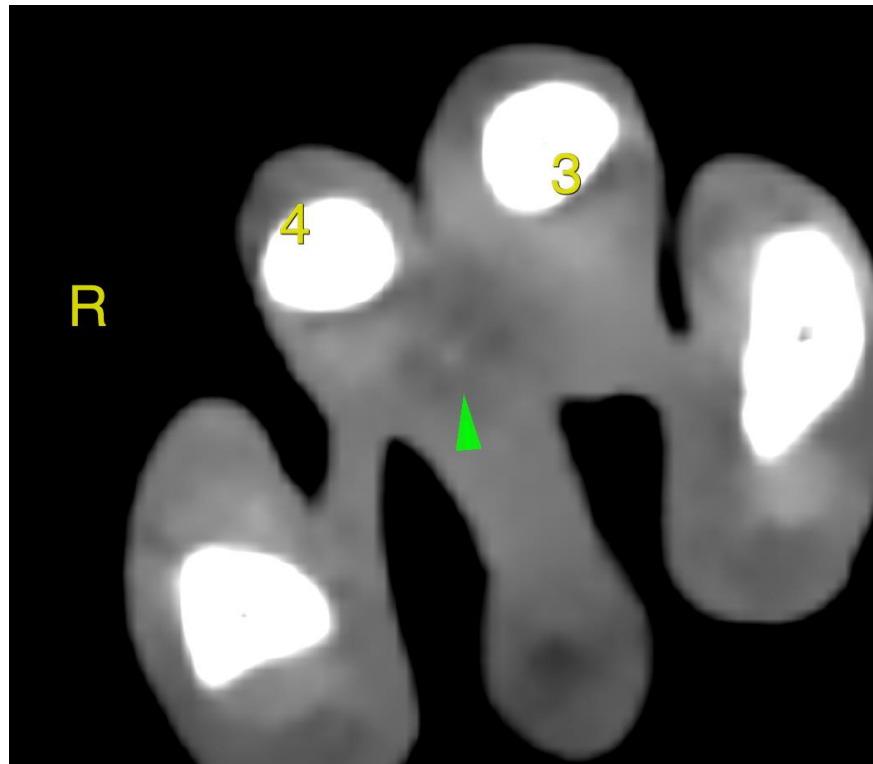
Dr. Dan Lewer

INVOICE

55883

DATE

12-28-22



The information and recommendations provided are based on the images presented by the referring veterinarian/sonographer. No evaluation can be communicated regarding pathology that was not visible in the image/video clips provided.

Thank you for this referral. If the clinical or image interpretation does not parallel your findings or if I can be of any further assistance please contact me.

Nele Eley, DVM, Dr. med. vet., DipECVDI
European Specialist in Veterinary Diagnostic Imaging, Cert. Radiology,
Senior lecturer University of Giessen, Germany, Veterinary Faculty, Department of Radiology
Nele.Eley@sonopath.com