



**PATIENT**

Wasabi Lin

**PRESENTING CLINICAL SIGNS**

Exercise intolerance, panting and dyspnic???

**SPECIES**

Canine

**RADIOGRAPHIC STUDY OF THE THORAX**

Right lateral and ventrodorsal views totaling 2 images available for review.

The tip of the cranial lobes are not entirely included in the orthogonal view; however, the lungs are fully included in the lateral view.

**BREED**

Doodle

**RADIOGRAPHIC FINDINGS**

The surrounding bony structures are within normal limits.

**SEX**

Female Intact

The extrathoracic soft tissues present homogeneous without abnormalities.

The heart is of normal size and shape and there is no evidence of cardiac chamber or vascular enlargement. The pulmonary vasculature is within normal limits. The vertebral heart score is 9.5.

**AGE**

7 Months

The cranial mediastinum presents the expected soft tissue opacity. The mediastinal width is less than twice the width of the vertebral column at the same level.

The trachea is normal in diameter and presents the anticipated course. The luminal outline of the trachea is smooth.

**INTERPRETED BY**

Nele Eley, DVM  
Dr. med. Vet. DipECVDI

The bronchial tree presents with thin walls and tapers uniformly towards the periphery as expected.

The lung parenchyma presents the expected architecture and opacity. The intrapulmonary vascular branching is seen up to the third order lung vessels.

**HOSPITAL NAME**

New Bridge  
Veterinary Practice

The diaphragm is well delineated with even surface and the expected mild cranial bulging of the diaphragmatic cupola.

The stomach is post-prandial.

**REFERRING VET**

Dr. Abina Glennon

**RADIOGRAPHIC DIAGNOSIS**

- Radiographically normal age related thorax.

**INTERPRETATION OF THE FINDINGS & FURTHER RECOMMENDATIONS**

**INVOICE**

49284

The radiographic study reveals no evidence of structural bronchopulmonary or cardiovascular pathology. The findings are considered within age related normal limits. The good visibility of the bronchial tree is likely a function of the slim body condition.

**DATE**

12-28-21



**PATIENT**

Wasabi Lin

**SPECIES**

Canine

**BREED**

Doodle

**SEX**

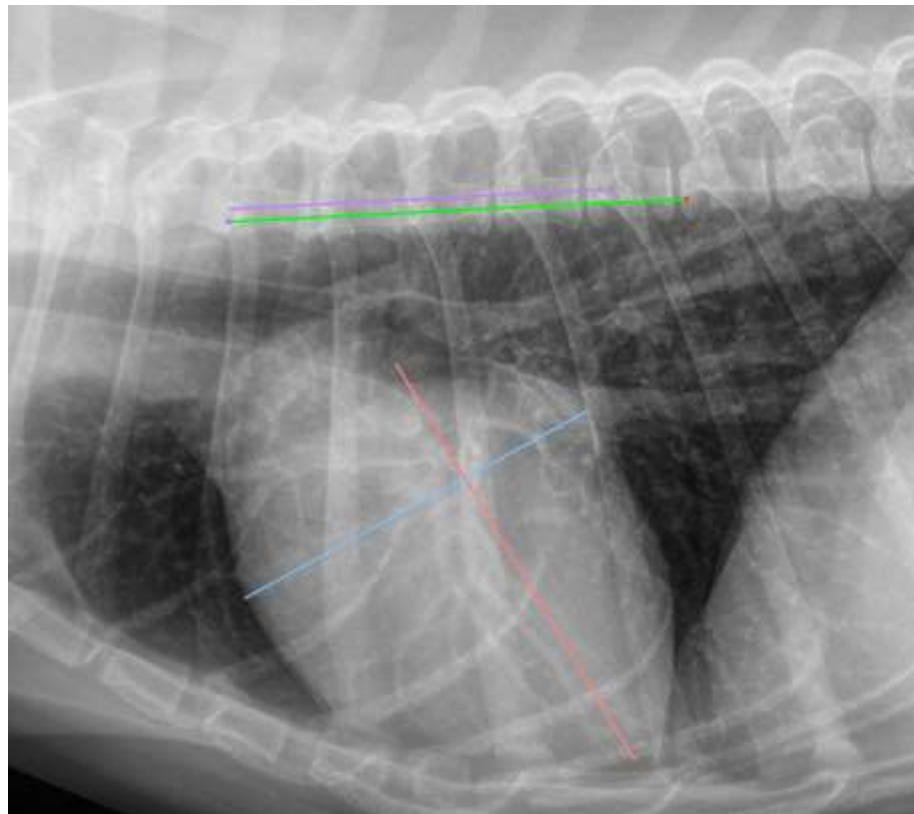
Female Intact

**AGE**

7 Months

**INTERPRETED BY**

Nele Eley, DVM  
Dr. med. Vet. DipECVDI



**HOSPITAL NAME**

New Bridge  
Veterinary Practice

**REFERRING VET**

Dr. Abina Glennon

**INVOICE**

49284

**DATE**

12-28-21

The information and recommendations provided are based on the images presented by the referring veterinarian. No evaluation can be communicated regarding pathology that was not visible in the image/video clips provided.

Thank you for this referral. If the clinical or image interpretation does not parallel your findings or if I can be of any further assistance please contact me.

**Nele Eley**, DVM, Dr. med. vet., DipECVDI  
European Specialist in Veterinary Diagnostic Imaging, Cert. Radiology,  
Senior lecturer University of Giessen, Germany, Veterinary Faculty, Department of Radiology  
Nele.Eley@sonopath.com