



**PATIENT**

Rascal Keator

**SPECIES**

Feline

**BREED**

DSH

**SEX**

Male Neutered

**AGE**

6 Years, 9 Months

**INTERPRETED BY**

Nele Eley, DVM  
Dr. med. Vet. DipECVDI

**HOSPITAL NAME**

Northvale Veterinary  
Clinic

**REFERRING VET**

Dr. Stefanie Simon

**INVOICE**

55843

**DATE**

12-26-22

**PRESENTING CLINICAL SIGNS**

Urinating only drops of urine for the past 12 hours and no defecating noted since yesterday. Eating fine and all else WNL.

Abnormal PE/Chem/CBC/UA Results: Small, soft bladder noted on palpation, all else WNL. CBC/Chem/UA pending.

**RADIOGRAPHIC STUDY OF THE ABDOMEN**

Right/left lateral and ventrodorsal views totaling 5 images available for review.

**RADIOGRAPHIC FINDINGS**

The patient has a sacrocaudal transitional vertebra.

The abdominal serosal detail is maintained.

The stomach is postprandial. The gastrointestinal tract presents within normal limits.

Both kidneys present within normal limits regarding their position, size, shape, and opacity. Focal concavities are noted within the lateral margin of the left kidney.

The urinary bladder is moderately distended. No evidence of radiopaque calculi is seen within the urinary bladder.

**RADIOGRAPHIC DIAGNOSIS**

- Suspect small cortical infarct of the left kidney.
- Normal radiographic presentation of the urinary bladder.
- Incidental congenital sacrocaudal transitional vertebra.

**INTERPRETATION OF THE FINDINGS & FURTHER RECOMMENDATIONS**

The radiographic study is negative for presence of radiopaque calculi within the urinary tract. Nonradiopaque calculi obstruction with hemo- or muco-plugs, lower urinary tract infection, and other cannot be ruled out as differential diagnoses and further definition by means of retrograde catheterization and abdominal ultrasound as well as full urinalysis could be considered if not performed already.



**PATIENT**

Rascal Keator

**SPECIES**

Feline

**BREED**

DSH

**SEX**

Male Neutered

**AGE**

6 Years, 9 Months

**INTERPRETED BY**

Nele Eley, DVM  
Dr. med. Vet. DipECVDI

**HOSPITAL NAME**

Northvale Veterinary  
Clinic

**REFERRING VET**

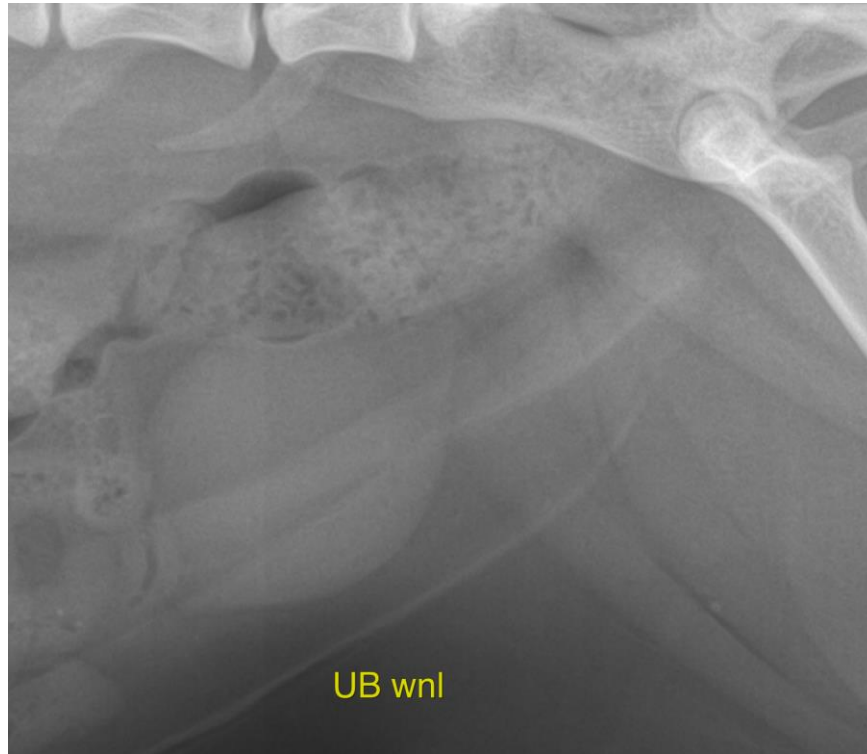
Dr. Stefanie Simon

**INVOICE**

55843

**DATE**

12-26-22



The information and recommendations provided are based on the images presented by the referring veterinarian/sonographer. No evaluation can be communicated regarding pathology that was not visible in the image/video clips provided.

Thank you for this referral. If the clinical or image interpretation does not parallel your findings or if I can be of any further assistance please contact me.

**Nele Eley**, DVM, Dr. med. vet., DipECVDI  
European Specialist in Veterinary Diagnostic Imaging, Cert. Radiology,  
Senior lecturer University of Giessen, Germany, Veterinary Faculty, Department of Radiology  
Nele.Eley@sonopath.com