



PATIENT

Eddie Recchio

PRESENTING CLINICAL SIGNS

acute inappetence, hx of FB ingestion in the past
Abnormal PE/Chem/CBC/UA Results: CBC/Chem/UA/T4 pending

SPECIES

Canine

RADIOGRAPHIC STUDY OF THE ABDOMEN

Right/left lateral and ventrodorsal views of the abdomen totaling 3 images available for review.

BREED

Cav King Charles

RADIOGRAPHIC FINDINGS

Early thoracolumbar spondylosis is seen.

The abdominal serosal detail is maintained.

SEX

MN

The liver, spleen, kidneys, and urinary bladder all present within normal radiographic limits.

The stomach contains a mild amount of food. There appear to be 3 polygonal shaped structures within the gastric fundus which range between soft tissue and mineral opacity.

AGE

8 Years

The small intestinal loops are evenly distributed throughout the mid abdomen. No evidence of abnormal dilation, plication, or radiopaque foreign material is seen.

The colon and cecum contain mainly gas and are in their anticipated position.

INTERPRETED BY

Nele Eley, DVM
Dr. med. Vet. DipECVDI

RADIOGRAPHIC DIAGNOSIS

- Suspect gastric foreign material.

INTERPRETATION OF THE FINDINGS & FURTHER RECOMMENDATIONS

HOSPITAL NAME

Boca Park Animal
Hospital

The radiographic findings suggest potential for presence of foreign matter within the stomach. However, I cannot rule out this representing edible material which then should pass the natural way. Consider further definition by means of ultrasound or a radiographic recheck with the patient being NPO 3-6 hours prior to the radiographs.

REFERRING VET

Laura Warren

INVOICE

49245

DATE

12-26-21



PATIENT

Eddie Recchio

SPECIES

Canine

BREED

Cav King Charles

SEX

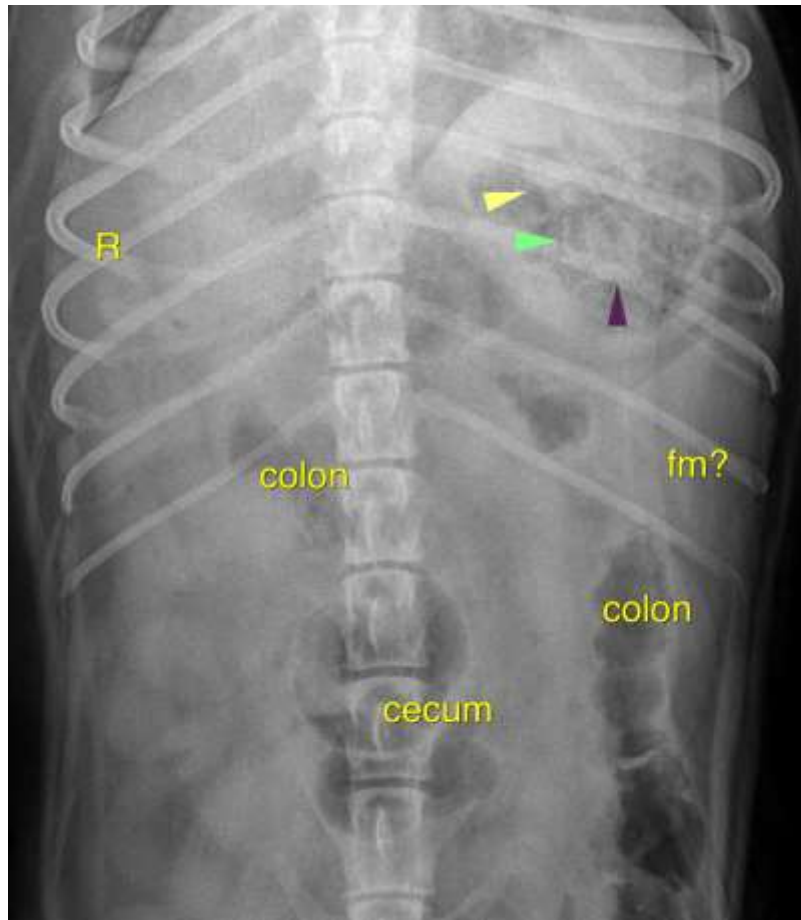
MN

AGE

8 Years

INTERPRETED BY

Nele Eley, DVM
Dr. med. Vet. DipECVDI



HOSPITAL NAME

Boca Park Animal
Hospital

REFERRING VET

Laura Warren

INVOICE

49245

DATE

12-26-21

The information and recommendations provided are based on the images presented by the referring veterinarian. No evaluation can be communicated regarding pathology that was not visible in the image/video clips provided.

Thank you for this referral. If the clinical or image interpretation does not parallel your findings or if I can be of any further assistance please contact me.

Nele Eley, DVM, Dr. med. vet., DipECVDI
European Specialist in Veterinary Diagnostic Imaging, Cert. Radiology,
Senior lecturer University of Giessen, Germany, Veterinary Faculty, Department of Radiology
Nele.Eley@sonopath.com