

**PATIENT**

Mabel Merrick

PRESENTING CLINICAL SIGNS

Right radius/ulna fracture this summer, was splinted at referring vet, developed malunion, now Mabel has an angular limb deformity of the right forelimb.

SPECIES

Canine

COMPUTED TOMOGRAPHIC STUDY OF THE FRONT LIMBS ELBOWS TO CARPI

Plain studies in bone and soft tissue windows available for review.

BREED

Goldendoodle

COMPUTED TOMOGRAPHIC FINDINGS

There is moderate to severe medial curvature of the right distal radius with carpus valgus position. The center of rotation is in the distal diaphyseal third of the radius. Medial deviation angle is approximately 35 degrees. No significant cranial or caudal curvature is noted.

SEX

F

The right radius is 3.0 cm shorter than the left radius and the right ulnar is 4.0 cm shorter than the left ulnar.

Both the distal radial and ulnar growth plates are closed.

AGE

9 Months

No evidence of elbow dysplasia is noted in either of the elbows.

COMPUTED TOMOGRAPHIC DIAGNOSIS

- Angular limb deformity after distal growth plate injury of the right forearm with moderate radius curvus and carpus valgus.
- Reduced longitudinal growth of the right radius and ulnar.

INTERPRETED BY

Nele Eley, DVM
Dr. med. Vet. DipECVDI

INTERPRETATION OF THE FINDINGS & FURTHER RECOMMENDATIONS**HOSPITAL NAME**

Animal Health
Partners

The CT findings suggest prior distal ulnar and potentially also distal right radius growth plate injury with malunion and angular limb deformity. 35 degree medial curvature with center of rotation in the distal diaphyseal third of the radius is seen. There is a moderate carpus valgus position. No evidence of cubital destruction is noted. The right radial longitudinal growth is reduced by 3.0 cm. The right ulnar longitudinal growth is reduced by 4.0 cm.

REFERRING VET

Dr. Debbie Reynolds

INVOICE

49240

DATE

12-23-21



PATIENT

Mabel Merrick

SPECIES

Canine

BREED

Goldendoodle

SEX

F

AGE

9 Months

INTERPRETED BY

Nele Eley, DVM
Dr. med. Vet. DipECVDI

HOSPITAL NAME

Animal Health
Partners

REFERRING VET

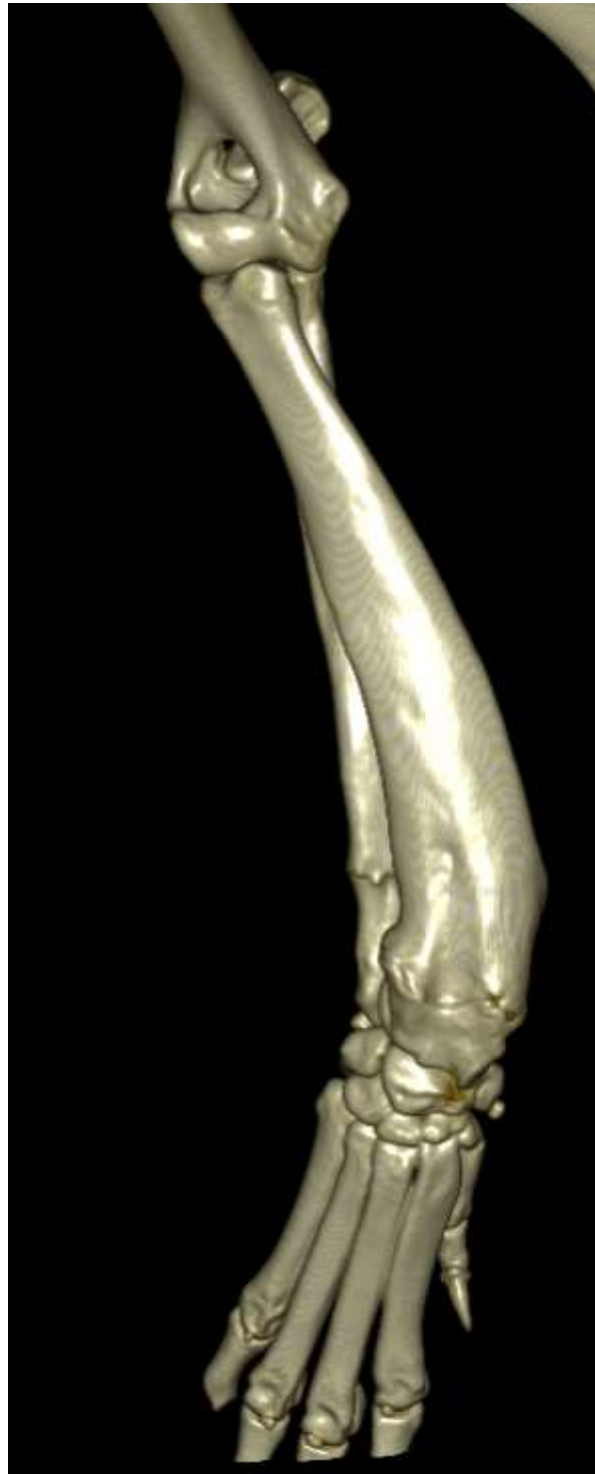Dr. Debbie Reynolds

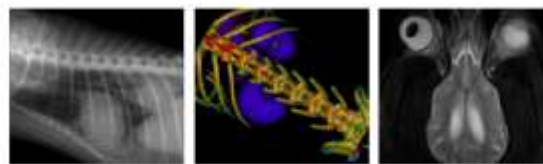
INVOICE

49240

DATE

12-23-21





PATIENT

Mabel Merrick

SPECIES

Canine

BREED

Goldendoodle

SEX

F

AGE

9 Months

INTERPRETED BY

Nele Eley, DVM
Dr. med. Vet. DipECVDI

HOSPITAL NAME

Animal Health
Partners

REFERRING VET

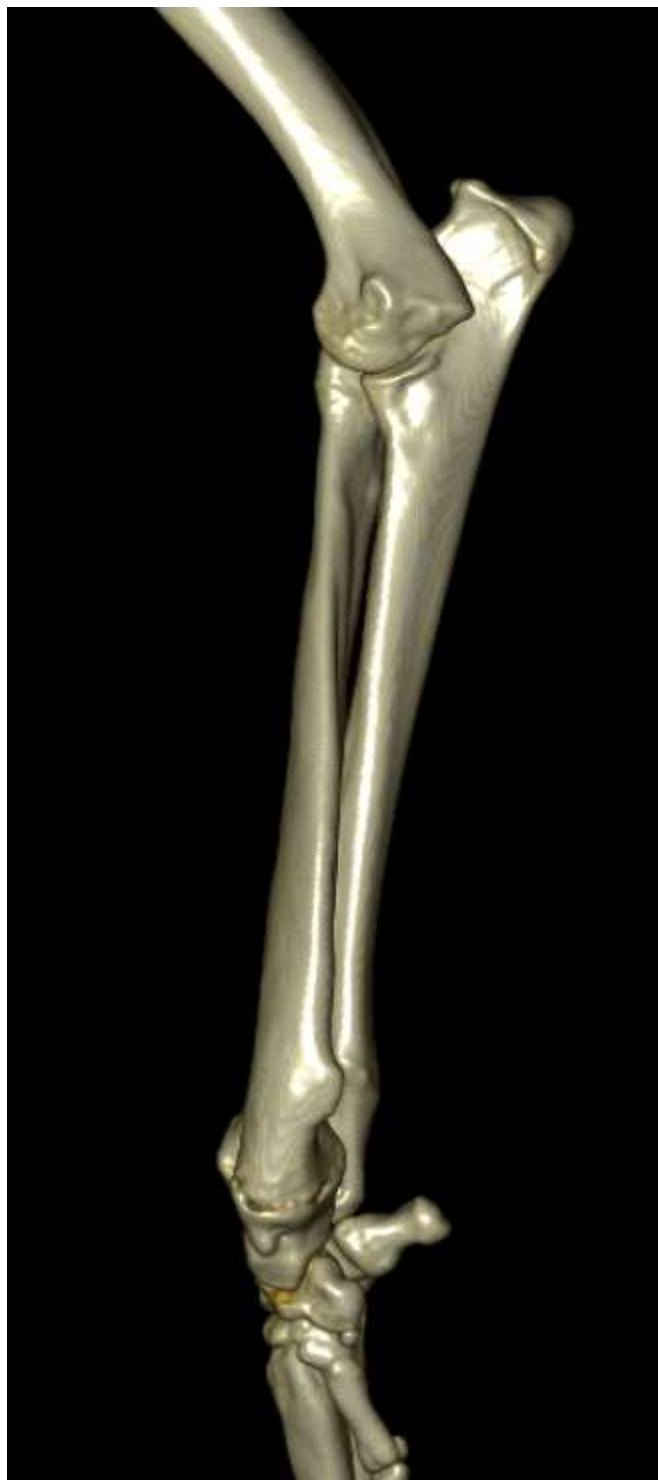Dr. Debbie Reynolds

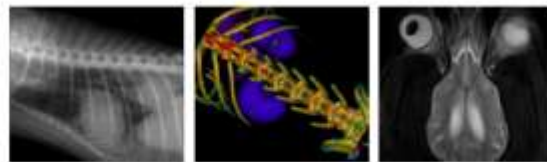
INVOICE

49240

DATE

12-23-21





PATIENT

Mabel Merrick

SPECIES

Canine

BREED

Goldendoodle

SEX

F

AGE

9 Months

INTERPRETED BY

Nele Eley, DVM
Dr. med. Vet. DipECVDI

HOSPITAL NAME

Animal Health
Partners

REFERRING VET

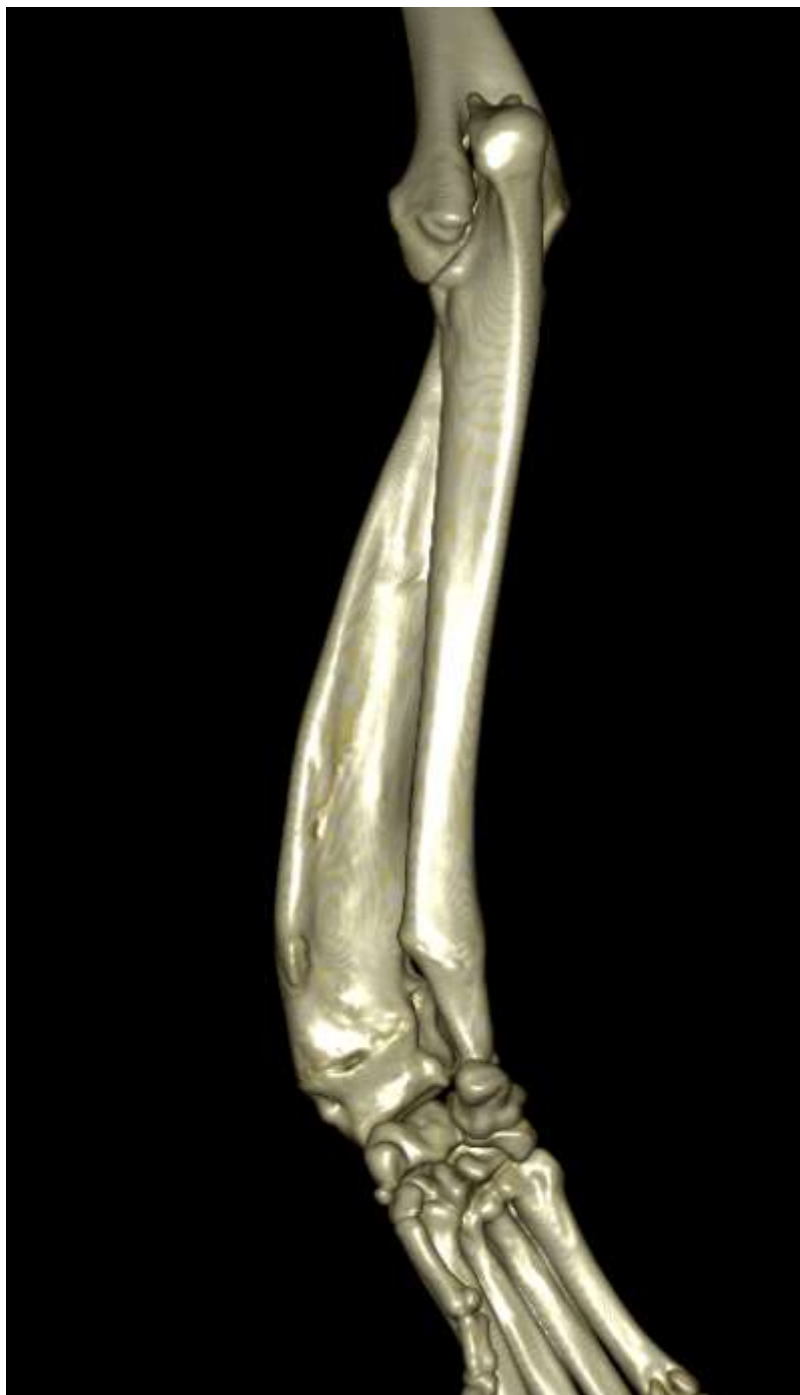Dr. Debbie Reynolds

INVOICE

49240

DATE

12-23-21





PATIENT

Mabel Merrick

SPECIES

Canine

BREED

Goldendoodle

SEX

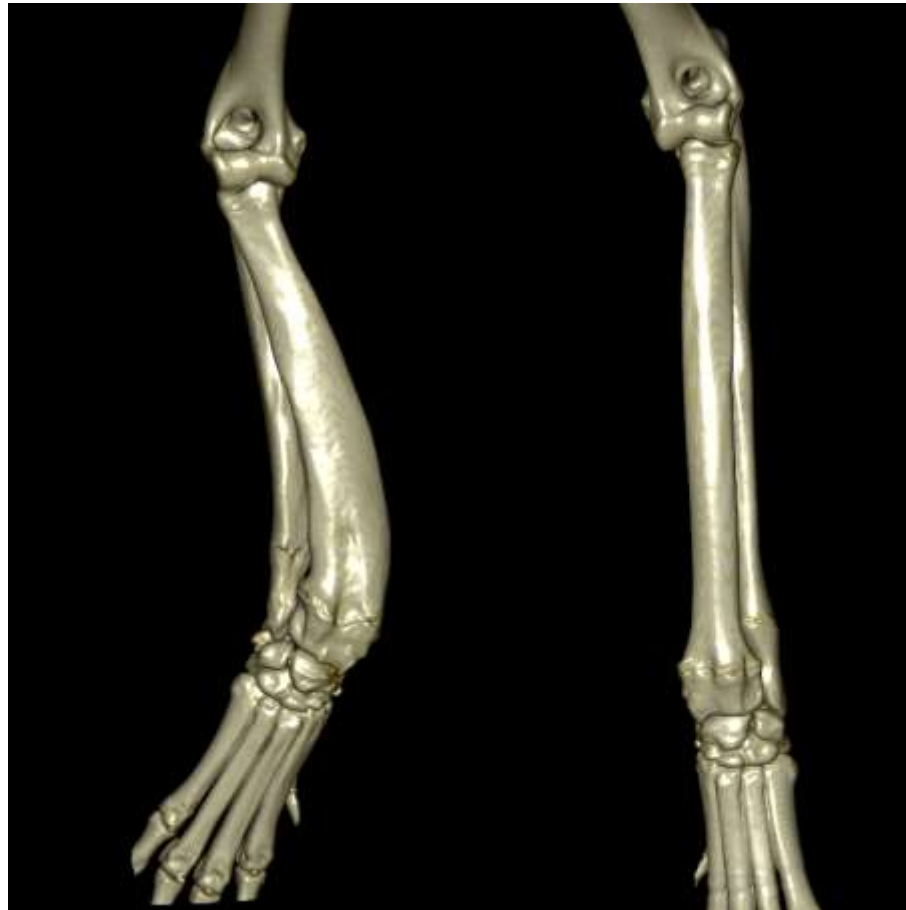F

AGE

9 Months

INTERPRETED BY

Nele Eley, DVM
Dr. med. Vet. DipECVDI



HOSPITAL NAME

Animal Health
Partners

REFERRING VET

Dr. Debbie Reynolds

INVOICE

49240

DATE

12-23-21

The information and recommendations provided are based on the images presented by the referring veterinarian. No evaluation can be communicated regarding pathology that was not visible in the image/video clips provided.

Thank you for this referral. If the clinical or image interpretation does not parallel your findings or if I can be of any further assistance please contact me.

Nele Eley, DVM, Dr. med. vet., DipECVDI
European Specialist in Veterinary Diagnostic Imaging, Cert. Radiology,
Senior lecturer University of Giessen, Germany, Veterinary Faculty, Department of Radiology
Nele.Eley@sonopath.com