



PATIENT

Dee Dee Greggo

PRESENTING CLINICAL SIGNS

Went to reg vet for dental, complications with the dental that caused infection afterwards. P went and had another dental with a different vet. Since then P has been acting neurological. Has been star gazing, staring off into space, no true seizures, not E/D well according to O and very depressed at home.

SPECIES

K9

Abnormal PE/Chem/CBC/UA Results: pH mildly low, plt 638, WBC 29k, NEU 27k, lipase 286, ALP >993, ALT 187, cholesterol high, BUN 8.5

BREED

Boston Terrier Mix

COMPUTED TOMOGRAPHIC STUDY OF THE HEAD, THORAX, & ABDOMEN

Plain and post contrast studies of the head, thorax, and abdomen available for review.

COMPUTED TOMOGRAPHIC FINDINGS

SEX

FS

Head

A 2.1 cm sized heterogeneously enhancing extra-axial mass is seen to the left of the midline level with the brainstem. The mass extends from the cerebellopontine angle to the caudal margin of the foramen magnum. Moderate to severe dorsal and rightward deviation of the brainstem is noted.

AGE

10 Years

The left tympanic bulla is filled with fluid attenuating contrast negative material. Mild thickening of the osseous lining of the tympanic bulla is seen.

INTERPRETED BY

Nele Eley, DVM
Dr. med. Vet. DipECVDI

The dentition is incomplete. Multiple teeth are absent. Root remnants of the triadans 101 and 210 are seen. There is moderate horizontal atrophy of the alveolar crest in all quadrants.

Thorax

The bony and surrounding soft tissue structures are within normal limits.

HOSPITAL NAME

Animal Emergency
Hospital Volusia

The sternal, cranial mediastinal and tracheobronchial lymph nodes are small elongated with a normal short-to-long-axis-ratio is < 0.5, the attenuation and contrast enhancement pattern are uniform and considered within normal limits.

REFERRING VET

Dr. Van Nieuwal

The cardiovascular structures including the pulmonary vasculature are within normal limits.

Moderate atelectatic changes accentuating the left lung and the left cranial lung lobe are seen. No evidence of structural pulmonary disease is seen.

INVOICE

49193

Small incidental gas pockets are seen within the esophageal lumen, there is no evidence of abnormal dilation.

Abdomen

DATE

12-23-21

The serosal fat presents normal attenuation behavior. There is no evidence of peritoneal effusion or peritonitis.

Both kidneys present within normal limits for size, shape and organ architecture. After contrast

**PATIENT**

administration a bilaterally symmetric and uniform nephro- and pyelogram is noted.

Dee Dee Greggo

The adrenal glands are within normal limits for size, shape and organ architecture.

SPECIES

The spleen presents diffuse heterogeneous enhancement with occasional small hyperenhancing nodules.

K9

Occasional small cysts are seen within the central and right divisions of the liver.

BREED

The pancreas is evenly contoured, the pancreatic parenchyma is homogeneous and presents uniform contrast enhancement.

Boston Terrier Mix

The position, delineation, wall and content of the gastrointestinal tract are considered within normal limits throughout.

SEX

The bony and surrounding soft tissue structures reveal no abnormalities.

FS

COMPUTED TOMOGRAPHIC DIAGNOSIS

- Extra-axial intracranial mass with mass effect onto the brainstem.
- Chronic left sided otitis media.
- Heterogeneous splenic enhancement with small nodules.
- Uncomplicated liver cysts.

AGE

10 Years

INTERPRETED BY

Nele Eley, DVM
Dr. med. Vet. DipECVDI

INTERPRETATION OF THE FINDINGS & FURTHER RECOMMENDATIONS

The main finding is the presence of an extra-axial contrast enhancing intracranial mass with mass effect onto the brainstem. The CT findings meet neoplastic criteria. Differential diagnosis includes meningioma, peripheral nerve sheath tumor, and round cell neoplasia.

HOSPITAL NAME

Animal Emergency
Hospital Volusia

Differential diagnosis for the splenic nodules includes benign nodular hyperplasia, extramedullary hematopoiesis, and less likely neoplastic infiltrate.

REFERRING VET

Dr. Van Nieuwal

INVOICE

49193

DATE

12-23-21



PATIENT

Dee Dee Greggo

SPECIES

K9

BREED

Boston Terrier Mix

SEX

FS

AGE

10 Years

INTERPRETED BY

Nele Eley, DVM
Dr. med. Vet. DipECVDI

HOSPITAL NAME

Animal Emergency
Hospital Volusia

REFERRING VET

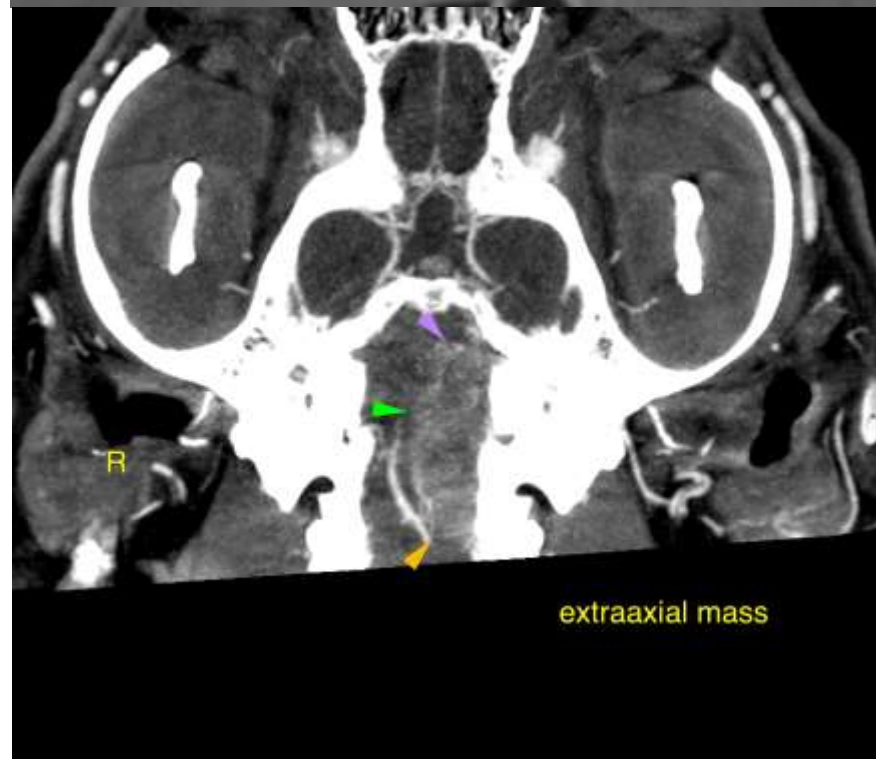
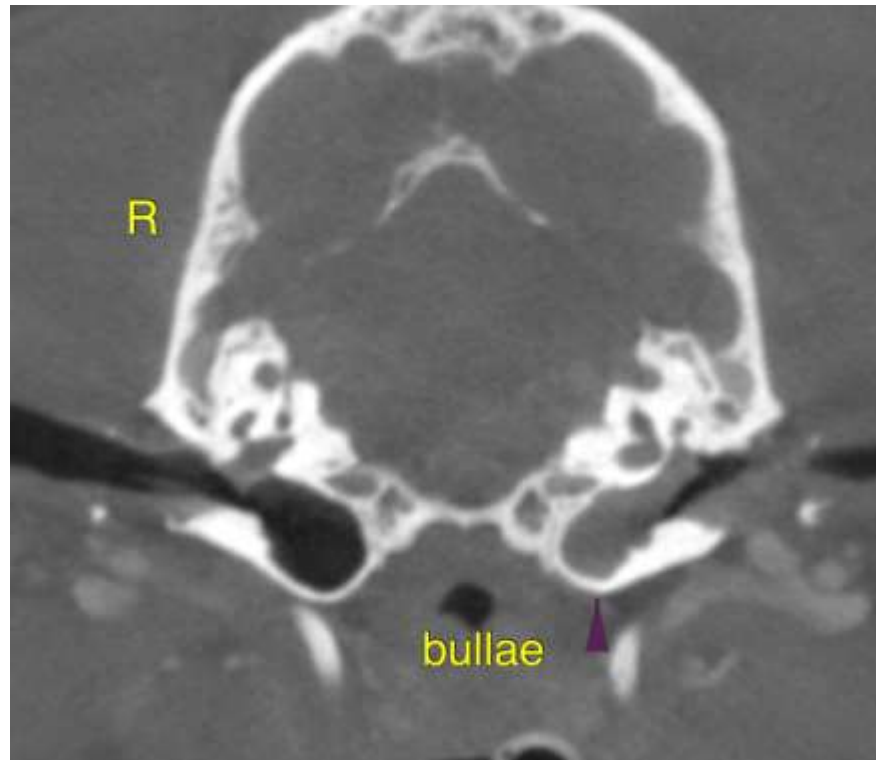
Dr. Van Nieuwal

INVOICE

49193

DATE

12-23-21





PATIENT

Dee Dee Greggo

The information and recommendations provided are based on the images presented by the referring veterinarian. No evaluation can be communicated regarding pathology that was not visible in the image/video clips provided.

SPECIES

K9

Thank you for this referral. If the clinical or image interpretation does not parallel your findings or if I can be of any further assistance please contact me.

BREED

Boston Terrier Mix

Nele Eley, DVM, Dr. med. vet., DipECVDI
European Specialist in Veterinary Diagnostic Imaging, Cert. Radiology,
Senior lecturer University of Giessen, Germany, Veterinary Faculty, Department of Radiology
Nele.Eley@sonopath.com

SEX

FS

AGE

10 Years

INTERPRETED BY

Nele Eley, DVM
Dr. med. Vet. DipECVDI

HOSPITAL NAME

Animal Emergency
Hospital Volusia

REFERRING VET

Dr. Van Nieuwal

INVOICE

49193

DATE

12-23-21