



PATIENT

Barkley Enslin

PRESENTING CLINICAL SIGNS

Got into the dirty laundry basket Friday and may have eaten some socks and underwear. Losson said that he has eaten dirty laundry before but he has thrown it back up. Started to have Diarrhea Sunday and that has stopped now he is vomiting everything up when he eats he turns around and throws that up and same with water.

SPECIES

Canine

Abnormal PE/Chem/CBC/UA Results: PE: Dehydrated the rest of the exam was normal. NO RESENT LABS

BREED

French Bulldog

RADIOGRAPHIC STUDY OF THE ABDOMEN

Right/left lateral and ventrodorsal views totaling 3 images available for review.

SEX

Neutered

RADIOGRAPHIC FINDINGS

Moderate lumbosacral spondylosis is seen. There is a series of congenital hemivertebrae in the mid and caudal thoracic spine from T6 through T11. Mild ventrally bridging spondyloses are seen.

No abnormalities of the extraabdominal soft tissues are noted. The abdominal wall is smooth and thin.

AGE

4 Years

The serosal detail is maintained throughout the peritoneal and retroperitoneal space.

The liver is appropriate in position, size and presents uniform opacity.

INTERPRETED BY

Nele Eley, DVM
Dr. med. Vet. DipECVDI

The splenic head is in the anticipated position and within normal limits for size and opacity. The splenic body and tail are considered normal for position, size, shape and opacity.

Both kidneys are seen and present with normal size, shape, delineation and opacity. The urinary bladder is in its anticipated position. No radiopaque calculi are noted throughout the upper and lower urinary tract.

HOSPITAL NAME

Elizabeth Animal Hospital

The stomach contains a mild amount of soft tissue opaque material compatible with food and a moderate amount of gas.

The small intestinal loops are turgid in appearance with predominantly gas content. One dilated bowel loop with striated mixed soft tissue and gas opaque content is seen in the right lateral view which might represent fabric as per the radiographic appearance. However, the findings are not repeated in the left lateral and orthogonal views.

REFERRING VET

Kim Allyn, DVM

The colon is largely empty.

INVOICE

49239

RADIOGRAPHIC DIAGNOSIS

- Possible fabric type intestinal foreign material.
- Unrelated: congenital vertebral malformations and degenerative lumbosacral stenosis.

DATE

12-23-21

INTERPRETATION OF THE FINDINGS & FURTHER RECOMMENDATIONS

Both the clinical history and the radiographic findings suggest potential for oral intake of textile foreign material. No overt radiographic signs for complete mechanical small ileus are seen at this



PATIENT

Barkley Enslin

point; however, the appearance of one bowel loop in the right lateral view is suspicious and further verification by means of abdominal ultrasound is strongly recommended in this patient.

SPECIES

Canine

BREED

French Bulldog

SEX

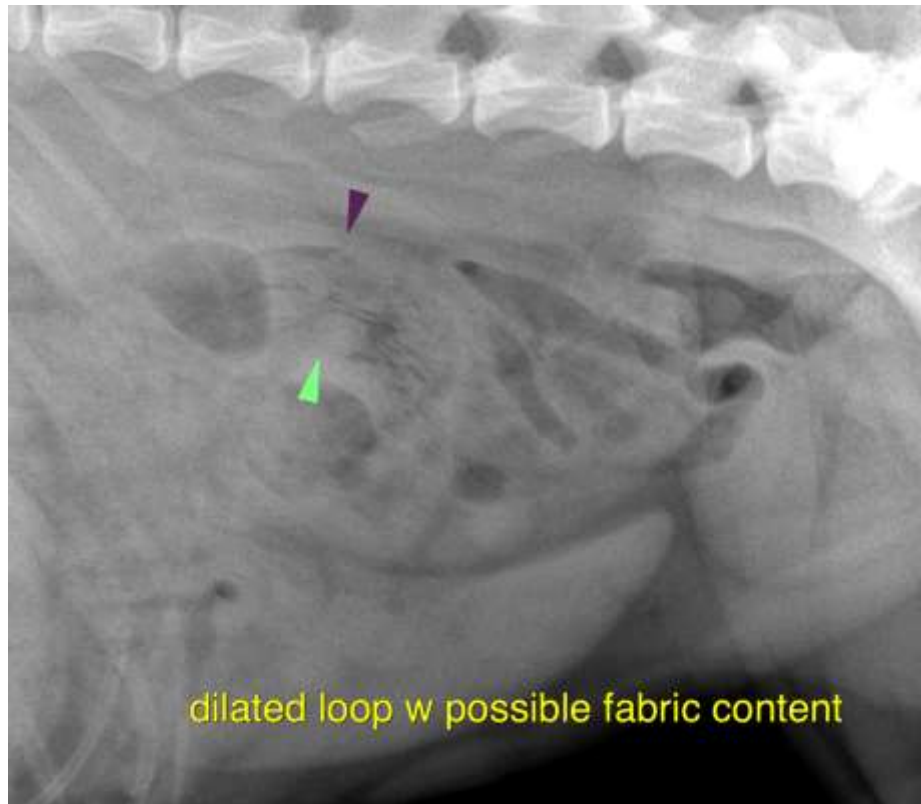
Neutered

AGE

4 Years

INTERPRETED BY

Nele Eley, DVM
Dr. med. Vet. DipECVDI



HOSPITAL NAME

Elizabeth Animal
Hospital

The information and recommendations provided are based on the images presented by the referring veterinarian. No evaluation can be communicated regarding pathology that was not visible in the image/video clips provided.

Thank you for this referral. If the clinical or image interpretation does not parallel your findings or if I can be of any further assistance please contact me.

REFERRING VET

Kim Allyn, DVM

Nele Eley, DVM, Dr. med. vet., DipECVDI
European Specialist in Veterinary Diagnostic Imaging, Cert. Radiology,
Senior lecturer University of Giessen, Germany, Veterinary Faculty, Department of Radiology
Nele.Eley@sonopath.com

INVOICE

49239

DATE

12-23-21