

**PATIENT**

Aspen Pierce

**PRESENTING CLINICAL SIGNS**

acute onset of aggression and one focal seizure

**SPECIES**

Canine

**COMPUTED TOMOGRAPHIC STUDY OF THE HEAD**

Plain and post contrast studies available for review.

**BREED**

Mixed

**COMPUTED TOMOGRAPHIC FINDINGS**

The pituitary gland appears to be prominent and wider than usual; however, the pituitary gland height is within normal limits and less than 5mm. No significant mass effect can be seen. The remainder of the neuroparenchyma presents the expected symmetry, attenuation, and enhancement.

**SEX**

FS

Thin and smoothly folded conchae and turbinates with even smooth mucosal lining.

Both temporomandibular joints present congruent joint spaces with even subchondral bone surfaces and are considered within normal limits.

**AGE**

7 Years

Both tympanic bullae are aerated, the mucosal lining is not seen, the bony wall is smooth and thin. The external auditory meatuses present within normal limits.

The submandibular and medial retropharyngeal lymph nodes are small and elongated with a normal short-to-long-axis-ratio is  $< 0.5$ , the attenuation and contrast enhancement pattern is uniform.**INTERPRETED BY**Nele Eley, DVM  
Dr. med. Vet. DipECVDI

The salivary glands present within normal limits.

Triadan 108 is absent.

**HOSPITAL NAME**Advanced Animal  
Imaging**COMPUTED TOMOGRAPHIC DIAGNOSIS**

- Suspect mild enlargement of the pituitary gland - otherwise normal CT findings of the brain.

**REFERRING VET**

Blair Hollowell, DVM

**INTERPRETATION OF THE FINDINGS & FURTHER RECOMMENDATIONS**

The pituitary gland appears to be wider than usual. Early adenoma or other suprasellar extraaxial neoplasia cannot be ruled out entirely. However, this may also represent a normal anatomic variant. No other structural neuroparenchymal changes are identified. An MRI study of the brain could be considered should the patient remain unresponsive to the anticonvulsive medication and should the csf analysis remain inconclusive.

**INVOICE**

49205

**DATE**

12-23-21



**PATIENT**

Aspen Pierce

**SPECIES**

Canine

**BREED**

Mixed

**SEX**

FS

**AGE**

7 Years

**INTERPRETED BY**

Nele Eley, DVM  
Dr. med. Vet. DipECVDI

**HOSPITAL NAME**

Advanced Animal  
Imaging

**REFERRING VET**

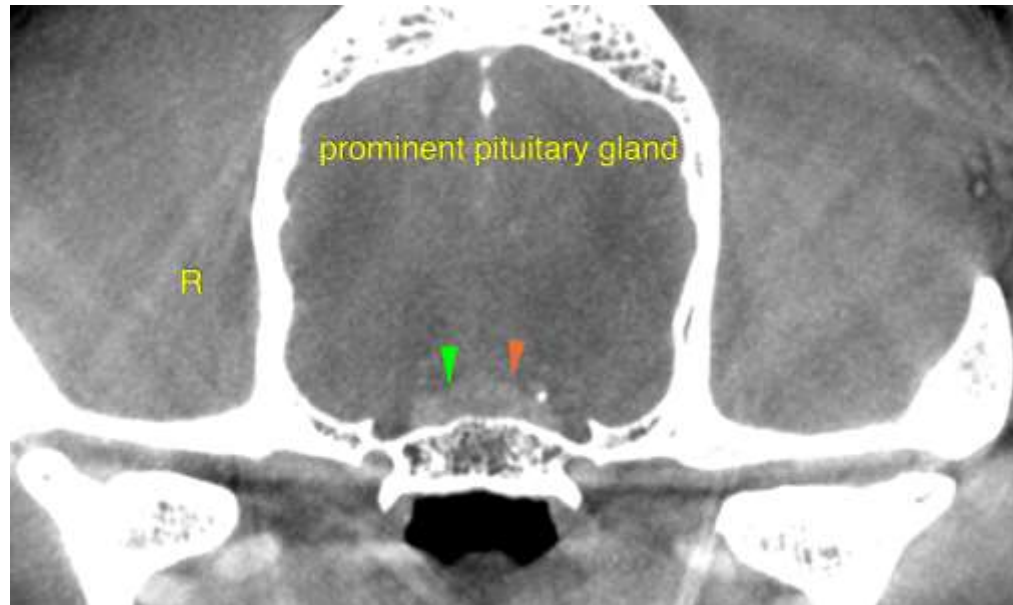
Blair Hollowell, DVM

**INVOICE**

49205

**DATE**

12-23-21



The information and recommendations provided are based on the images presented by the referring veterinarian. No evaluation can be communicated regarding pathology that was not visible in the image/video clips provided.

Thank you for this referral. If the clinical or image interpretation does not parallel your findings or if I can be of any further assistance please contact me.

**Nele Eley**, DVM, Dr. med. vet., DipECVDI  
European Specialist in Veterinary Diagnostic Imaging, Cert. Radiology,  
Senior lecturer University of Giessen, Germany, Veterinary Faculty, Department of Radiology  
Nele.Eley@sonopath.com