



PATIENT

Odin Perry

SPECIES

Canine

BREED

Labradoodle

SEX

Male N

AGE

7Y

WEIGHT

84.9lbs

INTERPRETED BY

Nele Eley (Ondreka),
DVM Dr. med. vet.,
DipECVDI

IMAGING PERFORMED BY

CG Vet Clinic

HOSPITAL NAME

Cottage Grove
Veterinary Clinic

REFERRING VET

Damewood

INVOICE

73080

DATE

12-22-25

PRESENTING CLINICAL SIGNS

Was treated for pneumonia.

RADIOGRAPHIC STUDY OF THE THORAX

Right/left lateral and ventrodorsal views of the thorax totaling 3 images available for review.

RADIOGRAPHIC FINDINGS

The overall cardiac size is within normal limits. The VHS is approximately 10.3. Mild left atrial tenting is suspected without evidence of pulmonary venous congestion or cardiogenic pulmonary edema.

A mild generalized bronchial lung pattern is present. There are no alveolar or interstitial infiltrates identified.

The mediastinum is normal in width and opacity. No evidence of mediastinal mass effects or lymphadenopathy is seen.

The pleural space presents within normal limits.

Mild spondylosis deformans is noted at T9/10.

RADIOGRAPHIC DIAGNOSIS

- Mild generalized bronchial pattern.
- Suspect mild left atrial tenting of uncertain clinical significance.
- No radiographic evidence of cardiogenic pulmonary edema or active pneumonia at this time.

INTERPRETATION OF FINDINGS & FURTHER RECOMMENDATIONS

The radiographic study reveals a mild generalized bronchial pattern which may be consistent with chronic or resolving inflammatory airway disease and could be a residual change following prior pneumonia. Evidence of active pneumonic infiltrate is not present radiographically at this time. Correlate with clinical findings and response to therapy.

If cardiac disease is a clinical concern and a cardiac murmur is detected, echocardiography may be helpful to further assess for the possibility of mild left atrial enlargement. Evidence of overall cardiomegaly, left ventricular enlargement, or congestive cardiac failure is not present.



PATIENT

Odin Perry

SPECIES

Canine

BREED

Labradoodle

SEX

Male N

AGE

7Y

WEIGHT

84.9lbs

INTERPRETED BY

Nele Eley (Ondreka),
DVM Dr. med. vet.,
DipECVDI

IMAGING PERFORMED BY

CG Vet Clinic

HOSPITAL NAME

Cottage Grove
Veterinary Clinic

REFERRING VET

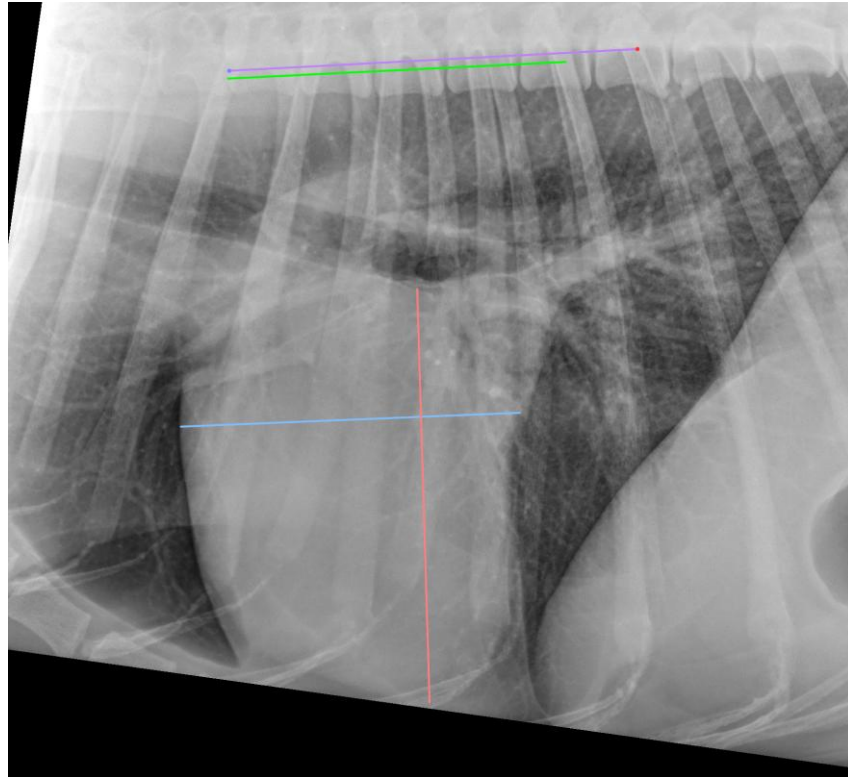
Damewood

INVOICE

73080

DATE

12-22-25



The information and recommendations provided are based on the images presented by the referring veterinarian. No evaluation can be communicated regarding pathology that was not visible in the image/video clips provided.

Thank you for this referral. If the clinical or image interpretation does not parallel your findings or if I can be of any further assistance please contact me.

Nele Eley (Ondreka), DVM, Dr. med. vet., DipECVDI
European Specialist in Veterinary Diagnostic Imaging, Cert. Radiology,
Senior lecturer University of Giessen/Germany, Veterinary Faculty, Department of Radiology.
info@sonopath.com