



PATIENT

Moxie Beard

SPECIES

Canine

BREED

Chihuahua

SEX

Female S

AGE

8Y

WEIGHT

12.5lbs

INTERPRETED BY

Nele Eley (Ondreka),
DVM Dr. med. vet.,
DipECVDI

IMAGING PERFORMED BY

CG Vet Clinic

HOSPITAL NAME

Cottage Grove
Veterinary Clinic

REFERRING VET

Damewood

INVOICE

73095

DATE

12-22-25

PRESENTING CLINICAL SIGNS

Coughing, wheezing, possible collapsing trachea

RADIOGRAPHIC STUDY OF THE THORAX

Right lateral and ventrodorsal views of the thorax totaling 2 images available for review.

RADIOGRAPHIC FINDINGS

The cardiac silhouette is normal in size and shape. The VHS is 10. No radiographic evidence of cardiomegaly or other cardiac remodeling to explain the cough is seen.

The cervical trachea shows redundant dorsal tracheal ligament suggestive of tracheal laxity. The thoracic trachea appears normal.

A mild generalized bronchial lung pattern with even distribution throughout the left and right lung is seen. No evidence of alveolar or interstitial infiltrates is noted. No pulmonary nodules are present.

The lateral view shows suboptimal lung inflation which may reflect respiratory phase or airway restriction.

The mediastinum presents within normal limits.

RADIOGRAPHIC DIAGNOSIS

- Mild generalized bronchial pattern.
- Cervical tracheal redundancy.
- No evidence of pulmonary nodules, infiltrates, or cardiac disease as cause for cough.

INTERPRETATION OF FINDINGS & FURTHER RECOMMENDATIONS

The findings support the suspicion of tracheal laxity represented by a redundant dorsal tracheal ligament which can be associated with dynamic tracheal disease even though no collapse is seen during the static radiographic examination.

The mild generalized bronchial pattern may reflect age related changes or mild chronic airway disease such as inflammatory and less likely infectious. Evidence of pneumonia, pulmonary masses, or cardiogenic disease is not identified currently. Clinical correlation with tracheal auscultation, fluoroscopy, or dynamic airway studies may help assess the degree of functional tracheal collapse.



PATIENT

Moxie Beard

SPECIES

Canine

BREED

Chihuahua

SEX

Female S

AGE

8Y

WEIGHT

12.5lbs

INTERPRETED BY

Nele Eley (Ondreka),
DVM Dr. med. vet.,
DipECVDI

IMAGING PERFORMED BY

CG Vet Clinic

HOSPITAL NAME

Cottage Grove
Veterinary Clinic

REFERRING VET

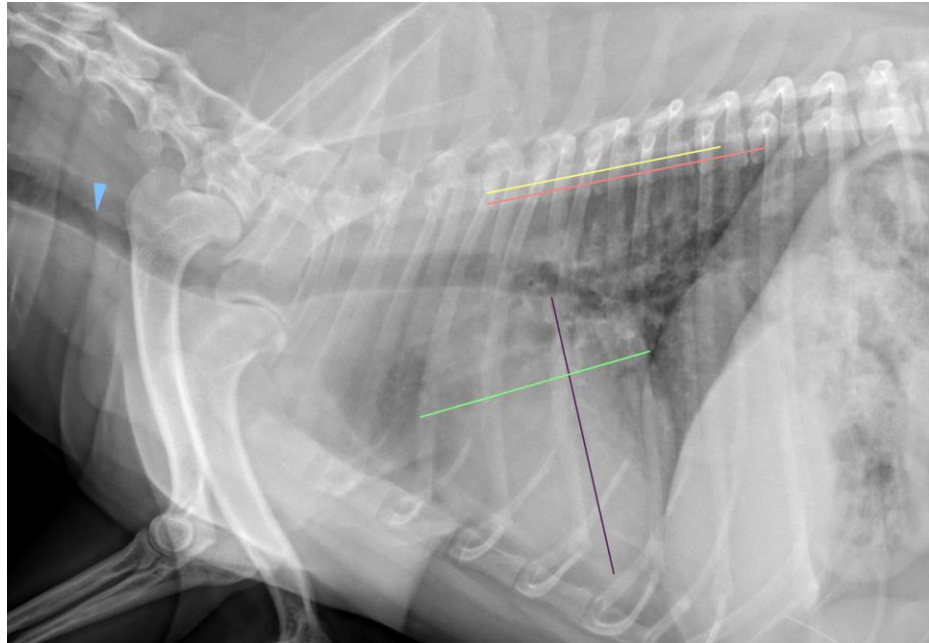
Damewood

INVOICE

73095

DATE

12-22-25



The information and recommendations provided are based on the images presented by the referring veterinarian. No evaluation can be communicated regarding pathology that was not visible in the image/video clips provided.

Thank you for this referral. If the clinical or image interpretation does not parallel your findings or if I can be of any further assistance please contact me.

Nele Eley (Ondreka), DVM, Dr. med. vet., DipECVDI
European Specialist in Veterinary Diagnostic Imaging, Cert. Radiology,
Senior lecturer University of Giessen/Germany, Veterinary Faculty, Department of Radiology.
info@sonopath.com