



PATIENT

Zelda Congiu

PRESENTING CLINICAL SIGNS

3 days history of reduced inappetence and vomiting
Abnormal PE/Chem/CBC/UA Results: unremarkable

SPECIES

Feline

RADIOGRAPHIC STUDY OF THE ABDOMEN

Right/left lateral and ventrodorsal views of the abdomen totaling 3 images available for review.

BREED

Domestic Shorthair

RADIOGRAPHIC FINDINGS

The surrounding bony structures are within normal limits.

No abnormalities of the extraabdominal soft tissues are noted. The abdominal wall is smooth and thin.

SEX

Female

The serosal detail is maintained throughout the peritoneal and retroperitoneal space.

The liver is appropriate in position, size and presents uniform opacity.

AGE

5 Months

The splenic head is in the anticipated position and within normal limits for size and opacity. The splenic tail is not seen.

Both kidneys are seen and present with normal size, shape, delineation and opacity. The urinary bladder is in its anticipated position. No radiopaque calculi are noted throughout the upper and lower urinary tract.

INTERPRETED BY

Nele Eley, DVM
Dr. med. Vet. DipECVDI

The stomach presents moderate aerophagia.

One small intestinal segment in the caudal abdomen presents mild dilation with fluid and gas. See image below. No radiopaque foreign material is seen. There is no evidence of small intestinal plication.

HOSPITAL NAME

St. Catherine's Animal
Hospital

The colon contains a mix of fecal matter and gas.

RADIOGRAPHIC DIAGNOSIS

- Suspect functional ileus versus subileus.

REFERRING VET

Dr. Boctor

INTERPRETATION OF THE FINDINGS & FURTHER RECOMMENDATIONS

The radiographic study reveals a short mildly dilated small intestinal segment. The changes are not definitive for mechanical ileus. Functional ileus could be the cause of the rather subtle dilation of the small intestinal segment even though subileus cannot be ruled out entirely. Consider narrow clinical monitoring with recheck radiographs or abdominal ultrasound in case of persisting or deteriorating clinical signs.

INVOICE

55797

DATE

12-22-22



PATIENT

Zelda Congiu

SPECIES

Feline

BREED

Domestic Shorthair

SEX

Female

AGE

5 Months

INTERPRETED BY

Nele Eley, DVM
Dr. med. Vet. DipECVDI

HOSPITAL NAME

St. Catherine's Animal
Hospital

REFERRING VET

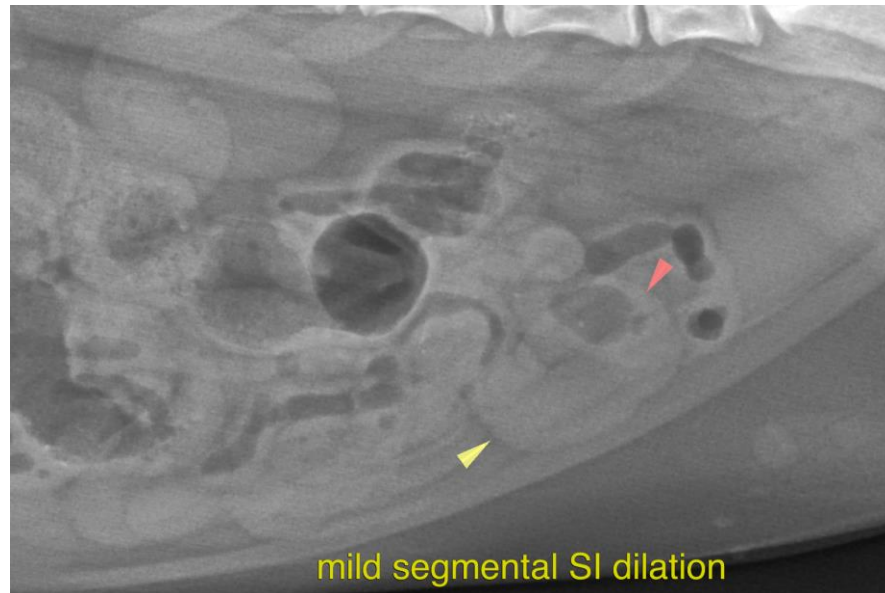
Dr. Boctor

INVOICE

55797

DATE

12-22-22



The information and recommendations provided are based on the images presented by the referring veterinarian/sonographer. No evaluation can be communicated regarding pathology that was not visible in the image/video clips provided.

Thank you for this referral. If the clinical or image interpretation does not parallel your findings or if I can be of any further assistance please contact me.

Nele Eley, DVM, Dr. med. vet., DipECVDI
European Specialist in Veterinary Diagnostic Imaging, Cert. Radiology,
Senior lecturer University of Giessen, Germany, Veterinary Faculty, Department of Radiology
Nele.Eley@sonopath.com